

## Best Practices



# Telemedicine During COVID-19 and Beyond: A Practical Guide and Best Practices Multidisciplinary Approach for the Orthopedic and Neurologic Pain Physical Examination

Sayed Wahezi, MD<sup>1</sup>, Robert A. Duarte, MD<sup>2</sup>, Sandeep Yerra, MBBS<sup>1</sup>, Mark A. Thomas, MD<sup>1</sup>, Beendu Pujar, MD<sup>1</sup>, Nalini Sehgal, MD<sup>3</sup>, Charles Argoff, MD<sup>1</sup>, Laxmaiah Manchikanti, MD<sup>4</sup>, David Gonzalez, MD<sup>1</sup>, Ruchi Jain, MD<sup>1</sup>, Chong Kim, MD<sup>1</sup>, Michael Hossack, MD<sup>1</sup>, Shayan Senthelal, MD<sup>1</sup>, Ankush Jain, MD<sup>1</sup>, Nathanael Leo, MD<sup>1</sup>, Naum Shaparin, MD<sup>1</sup>, Daniel Wong, MD<sup>1</sup>, Ashley Wong, MD<sup>1</sup>, Kim Nguyen, MD<sup>1</sup>, Jaspal Ricky Singh, MD<sup>5</sup>, Giacinto Grieco, MD<sup>2</sup>, Arpan Patel, MD<sup>2</sup>, Merritt D. Kinon, MD<sup>1</sup>, and Alan David Kaye, MD, PhD<sup>6</sup>

From: <sup>1</sup>Montefiore Medical Center, Bronx, NY; <sup>2</sup>Northwell Health, NY; <sup>3</sup>University of Wisconsin School of Medicine and Public Health, Madison, WI; <sup>4</sup>Pain Management Centers of America, Paducah, KY; <sup>5</sup>Weill Cornell Medicine, New York, NY; <sup>6</sup>LSU School of Medicine, Shreveport, LA and New Orleans, LA and Tulane School of Medicine, New Orleans, LA

Address Correspondence:  
Sandeep Yerra, MD  
Montefiore Medical Center  
Department of Rehabilitation  
Medicine  
150 E. 210th Street  
Bronx, NY 10467  
E-mail:  
drsandeepyerra@gmail.com

Disclaimer: There was no external funding in the preparation of this manuscript.

Conflict of interest:  
Dr. Kaye is a speaker for Merck.  
Dr. Wahezi is a consultant for Boston Dynamic.

Manuscript received: 05-20-2020  
Revised manuscript received:  
06-18-2020  
Accepted for publication:  
07-12-2020

Free full manuscript:  
www.painphysicianjournal.com

**Background:** The COVID pandemic has impacted almost every aspect of human interaction, causing global changes in financial, health care, and social environments for the foreseeable future. More than 1.3 million of the 4 million cases of COVID-19 confirmed globally as of May 2020 have been identified in the United States, testing the capacity and resilience of our hospitals and health care workers. The impacts of the ongoing pandemic, caused by a novel strain of severe acute respiratory syndrome coronavirus 2 (SARS-CoV-2), have far-reaching implications for the future of our health care system and how we deliver routine care to patients. The adoption of social distancing during this pandemic has demonstrated efficacy in controlling the spread of this virus and has been the only proven means of infection control thus far. Social distancing has prompted hospital closures and the reduction of all non-COVID clinical visits, causing widespread financial despair to many outpatient centers. However, the need to treat patients for non-COVID problems remains important despite this pandemic, as care must continue to be delivered to patients despite their ability or desire to report to outpatient centers for their general care. Our national health care system has realized this need and has incentivized providers to adopt distance-based care in the form of telemedicine and video medicine visits. Many institutions have since incorporated these into their practices without financial penalty because of Medicare's 1135 waiver, which currently reimburses telemedicine at the same rate as evaluation and management codes (E/M Codes). Although the financial burden has been alleviated by this policy, the practitioner remains accountable for providing proper assessment with this new modality of health care delivery. This is a challenge for most physicians, so our team of national experts has created a reference guide for musculoskeletal and neurologic examination selection to retrofit into the telemedicine experience.

**Objectives:** To describe and illustrate musculoskeletal and neurologic examination techniques that can be used effectively in telemedicine.

**Study Design:** Consensus-based multispecialty guidelines.

**Setting:** Tertiary care center.

**Methods:** Literature review of the neck, shoulder, elbow, wrist, hand, lumbar, hip, and knee physical examinations were performed. A multidisciplinary team comprised of physical medicine and rehabilitation, orthopedics, rheumatology, neurology, and anesthesia experts evaluated each examination and provided consensus opinion to select the examinations most appropriate for telemedicine evaluation. The team also provided consensus opinion on how to modify some examinations to incorporate into a nonhealth care office setting.

**Results:** Sixty-nine examinations were selected by the consensus team. Household objects were identified that modified standard and validated examinations, which could facilitate the examinations. The consensus review team did not believe that the modified tests altered the validity of the standardized tests.

**Limitations:** Examinations selected are not validated for telemedicine. Qualitative and quantitative analyses were not performed.

**Conclusions:** The physical examination is an essential component for sound clinical judgment and patient care planning. The physical examinations described in this manuscript provide a comprehensive framework for the musculoskeletal and neurologic examination, which has been vetted by a committee of national experts for incorporation into the telemedicine evaluation.

**Key words:** COVID, pain, telemedicine, physical examination, spine, shoulder, elbow, hand, hip, knee

**Pain Physician 2020: 23:S205-S237**

---

**A**s of May 28, 2020, the coronavirus COVID-19 death toll exceeded 100,000, even though the country as a whole remains eighth among the global population based on deaths per 100,000, causing unprecedented economic recession and health care crisis (1). The impacts of the ongoing pandemic, caused by a novel strain of severe acute respiratory syndrome coronavirus 2 (SARS-CoV-2), have far-reaching implications for the future of our health care system and how we deliver routine care to patients.

Nationally, the epidemiologic novelty of COVID-19 revealed vulnerabilities in existing supply chains, resulting in unprecedented social and economic disruptions and pressure on the health care system. In April, the U.S. Department of Health and Human Services released a report based on survey responses submitted by 323 hospitals, which detailed severe shortages of personal protective equipment (PPE), issues with adequate staffing levels, and a paucity of hospital capacity and ancillary supplies necessary to safely care for patients (2). Our health care system has addressed these challenges with innovative workarounds, including utilizing 3D-printed PPE, addressing capacity needs by reallocating physicians and nurses, and implementing electronic consultations (E-consults) for inpatient specialist services and televisits for the outpatient setting to adhere to social distancing guides for infection control, and to reserve PPE usage for health care workers in direct contact with COVID-infected patients.

COVID has changed how health care is practiced in the United States. It may permanently impact how we deliver care. Personal distancing during this time of COVID control has created an environment of social caution, and a need for clinical reform. The use of telemedicine has been on the rise in many regions and it is not evident when this trend will stop. Its use may be favored by patients who have difficulty traveling to physician offices, and some practitioners prefer telemedicine

for noncomplicated follow-up visits. However, patients with a new pain complaint can be challenging, as there is minimal education directed toward proper examination of these patients. There is a paucity of published literature on the subject. Graduate medical education does not recognize telemedicine as a competency for the pain specialist, making an evidence-based platform for the telemedicine physical examination in the near future unlikely (3). However, the authors maintain that the telemedicine musculoskeletal and neurologic physical examination can be assessed accurately if 4 principles are followed: (1) ability of the practitioner to perform an appropriate regional anatomic inspection; (2) while recognizing normal versus pathological motion; (3) proper preparation and utilization of electronic devices by the patient; and (4) appropriate direction of the patient by the physician. Here we deliver practical guidance for the understanding and execution of the physical examination that is fundamental for clinical decision-making.

The development of an effective and efficient telemedicine arm of a practice is dependent on education of specific members of the administration and clinical team. Because this service is very new in clinical literature and is underused even by the most experienced practitioners, the onus for improvement rests on practitioners who have been using the service often to report the benefits and pitfalls. A major aim of this investigation is to facilitate this process by introducing our recommendations.

The patient telemedicine video visit should simulate the environment of an office visit. Thus the patient's room should be well lit, free of noise and distraction, have seating and the space to stand and to walk short distances. Common household items, which will serve as props for the examination, must also be easily accessible. These examination props are outlined in the tables later. A kitchen usually fulfills most of the criteria

described earlier. Proper clothing is also required. For instance, shorts are to be worn for a below the waist complaint, and a T-shirt for above the waist examination. The physician's call center should inform the patient of these directions well before the visit. Proper preparation decreases the nonclinical instruction time during the visit. If the patient is using a phone for the video interaction, then the phone must be positioned self-standing on a sturdy surface so both of the patient's hands are available to perform tasks during the examination. The camera distance should be approximately 6 feet (2 m) away from the patient. For most patients, this is the appropriate distance for the practitioner to view a torso without having to relocate the device. The physician should be notified of the nature of the pain location prior to the visit so that the practitioner can be ready to guide the patient through the examination with their own set of props.

The telemedicine examination should be focused on the region of the pain and then extended beyond from that region depending on patients' symptoms of pain and their examination findings. The recommendations made in this review are meant to serve as guidelines only. Deciding which examination techniques to employ and when to use the technique goes beyond the scope of this manuscript. In many cases a diagnosis can be made with the directions provided here. However, it is at the discretion of the practitioner to perform an office visit if the recommendations here are insufficient to establish a diagnosis or uncover the need for an in-office visit for clarification of medical planning.

## METHODS

Twenty nationally recognized leaders in their fields who have been using telemedicine since its rise in popularity developed and cross-evaluated physical examinations for applicability to the telemedicine platform. The examinations chosen were based on the ease with which the practitioner could instruct patients properly, and on their adaptability to perform the motions safely in a nonoffice environment without changing validity. An expert group comprised of physical medicine and rehabilitation specialists, orthopedists, rheumatologists, neurologists, and anesthesiologists was tasked with creating a musculoskeletal or neurologic physical examination appropriate for incorporation into the virtual workup. Each specialist designed an anatomically based examination that they were most familiar with. For example, the shoulder examination was created by a board-certified sports medicine shoulder specialist;

however, all evaluators are skilled in every regional examination in this report. After creation of the region-based anatomic examination, all members of the group, as well as an outside committee comprised of the same specialties, reviewed, selected, and modified the examinations based on the same criteria.

## RESULTS

After multidisciplinary design, selection, and consensus, the tables in this article were created to guide musculoskeletal specialists in the physical examination. More than 100 examinations were reviewed. Sixty-nine examinations were selected by the group.

### Neck

Neck pain is one of the leading causes of disability, with an annual prevalence between 15% and 50% (4-9). Almost half of the individuals will continue to experience pain or suffer from recurrence. History and physical examination can provide important clues as to whether the pain is neuropathic or mechanical and can also be used to identify "red flags" that may signify serious pathology. A summary of instructions for the neck examination is provided in Table 1.

### Shoulder

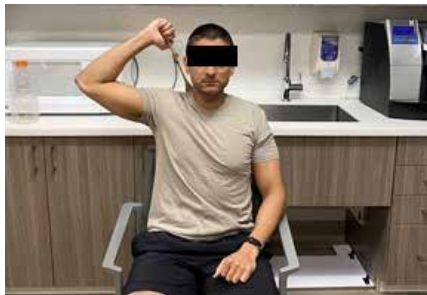A telemedicine examination of the shoulder should follow the principles of the general shoulder examination and begin with a thorough history, inspection, palpation, provocative tests, ROM, and strength testing (13). Shoulder pain encompasses a wide breadth of pathologies, including arthritis, rotator cuff pathology, instability, acromioclavicular joint pathology, biceps pathology, labral pathology, and infection, as well as conditions of the cervical spine masquerading as shoulder pain (14-18). A summary of instructions for the shoulder examination are summarized in Table 2.

### Hand/Wrist/Elbow

Evaluation of the hand/wrist/elbow is an integral aspect of assessing upper extremity functioning and musculoskeletal disorders. After a detailed clinical history, the examination may be targeted to the areas of concern. Thorough inspection of the hand/wrist and elbow, ROM/strength testing, along with specialized examinations for certain ligamentous/tendon abnormalities and carpometacarpal (CMC) degenerative disease may be performed via telemedicine. A summary of instructions for the hand/wrist/elbow examination are summarized in Table 3.

Table 1. *Guide to the modified neck examination through telemedicine.*

	Instruction	Clinical Value
Body Part	Neck Examination	
Previsit instructions	Ensure the patient has approximately 6 feet (2 m) free space in all directions.  Video device to be placed 6 feet (2 m) directly in front of patient and propped on a stable surface.	Mobility and position. Patient may be asked to sit and stand to observe balance and sit-stand position transition.
Physician props	Diagram of neck musculature and spine model.	Educate patient on neck anatomy to describe painful condition once examination is complete.
Patient props	12-inch ruler (30 cm) or wooden spoon.  Hand towel (~16-28 inches [40-70 cm] in length) for use with examination.	Long object used to point to painful area(s).  Force application across painful sites.
Patient clothing and prep	Collarless shirt.  Hair tied up if patient has long hair.	Allow visualization of examination areas.
General appearance	Sit or stand naturally facing the camera.	Chin deviation from midline. Identify behaviors indicative of pain or nonorganic pathology.
Symmetry	Sit or stand naturally facing the camera and away from the camera.	Muscle atrophy or winging or drooping of the shoulder (may be observed with radiculopathy, brachial plexopathy, or nerve entrapment).
Point to area of maximum pain	Using a wooden spoon, point to the area that is usually the most painful.	Helps to confirm patients description of pain area.



	Instruction	Clinical Value
Range of motion (ROM)	Move chin to touch the chest. Tilt head back. Turn neck to move the chin to the shoulder. Repeat to other side. Tilt head so that ear goes to the shoulder on one side. Repeat on other side.	Abnormal lateral or forward flexion, or rotation, may indicate torticollis.  Failure of chin to return to vertical/horizontal midline may suggest dystonia.

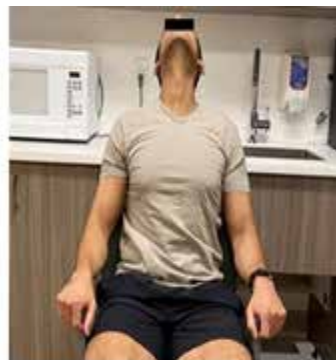
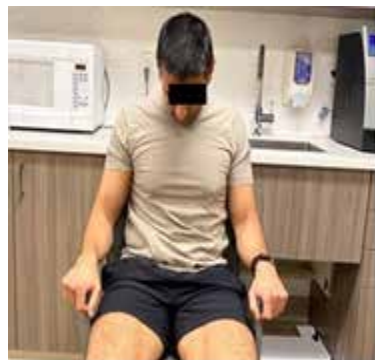
Table 1 (cont.). *Guide to the modified neck examination through telemedicine.*






	Instruction	Clinical Value
		
Shoulder abduction (Bakody sign)  Sensitivity 40%-60% Specificity 88%-90% (9)	Instruct the patient to place the hand on the painful side on top of the head.	Improvement of radicular symptoms suggests diagnosis of cervical radiculopathy.
		
	Instruction	Clinical Value
Valsalva  Sensitivity 22% Specificity 94% (10)	Instruct patient to “bear down” or try to breath out forcefully with their mouth and nose closed.	Referred electric sensation suggests cervical radiculopathy.
L’Hermitte sign  Sensitivity 65% Specificity 97% (11)	Instruct patient to rest their chin on their chest.	Shock-like sensation in arms/legs suggests cervical myelopathy or meningeal irritation.  Note: neck pain without electrical sensation suggests trapezius and/or splenius as source of pain.
		



Table 1 (cont.). *Guide to the modified neck examination through telemedicine.*

	Instruction	Clinical Value
Spurling test Sensitivity 40%-60% Specificity 85%-95% (12)	Instruct patient to put the folded lengthwise towel over their head, holding on to both ends.  Then have patient turn head toward the painful side so that the chin goes to the shoulder. Then have patient tilt the head so that the ear moves closer to the shoulder. If able, use the towel on the head to pull down toward the ground.	Cervical radiculopathy.
		
Jackson compression  Not validated for facet joint pain  93% specificity (12)  Sensitivity N/A	Instruct patient to put the folded lengthwise towel over their head, holding on to both ends.  Then have patient move the ear toward the shoulder. If able, use the towel on the head to pull down toward the ground.	Cervical radiculopathy/myelopathy. Believed to create facet load of mid-cervical facets (that project laterally C34 C45 C56 C67).
		

## Lumbar Spine

Lower back pain causes significant disability and social burden worldwide. Pain is a self-reported symptom that is subject to multiple biases, both from the patient and evaluating physician. Particularly with lower back pain, which can have a significant psychosocial component, a good objective physical examination is key to an accurate diagnostic workup. An accurate diagnosis is crucial when deciding on the appropriate treatment

and utilization of resources for favorable outcomes of lower back pain. Many different diagnoses present with similar clinical histories. Because of the anatomic location and multifactorial nature of lower back pain, identifying the source of pain has been especially challenging for clinicians. Nearly every element of the lower back (muscle, bone, nerve, disc, etc.) has been implicated as a cause of lower back pain. With our transition to telemedicine, it is crucial that we optimize our

Table 2. Guide to the modified shoulder examination through telemedicine guide.


	Instruction	Clinical Value	Images
Body Part	Shoulder Examination		
Previsit instructions	<p>Ensure the patient has approximately 3 feet free space in all directions.</p> <p>Video device to be placed 3 feet directly in front of patient and propped on a stable surface.</p>	<p>Mobility and position. Patient may be asked to sit and stand to observe balance and sit-stand position transition.</p>	
Physician props	Diagram of shoulder anatomy.	Educate patient on shoulder anatomy to describe painful condition once examination is complete.	
Patient props	Heavy cylindrical object, such as a can of pasta sauce or soda can.	Easy grasp object for muscle testing.	
Patient clothing	Tank top	Allows inspection of shoulder.	
Inspection	Examine the shoulders, arms, front and back looking for asymmetry, swelling, erythema, and wasting.	Any abnormal findings may help to establish a differential diagnosis.	
Palpation	Have the patient point to the area of maximum tenderness or pain. Use anatomic photos or models to assist.	<p>Tenderness in the anterior acromial region or greater tuberosity may indicate rotator cuff syndrome.</p> <p>Tenderness in the acromioclavicular (AC) joint may be indicative of arthritis or AC separation.</p>	
Shoulder Specific Tests			
<p>Jobe empty can test</p> <p>Sensitivity 52.6%</p> <p>Specificity of 82.4% for full-thickness supraspinatus tears (14)</p>	<p>Patient holds glass jar of pasta sauce (or equivalent). The patients arm is held in 90° of abduction with 30° of forward flexion and the arm is held in internal rotation so the thumb is pointing to the floor.</p>	<p>Weakness or pain may demonstrate a supraspinatus tear or rotator cuff impingement.</p> <p>Ability to hold weighted object upside down also tests grip strength.</p>	

Table 2 con't. *Guide to the modified shoulder examination through telemedicine guide.*





	Instruction	Clinical Value	Images
Hawkins test  Sensitivity 79% for subacromial impingement (15)  Specificity 59%	The shoulder is held in 90° of forward flexion with the elbow in 90° of flexion. The shoulder is internally rotated.	Pain may indicate subacromial impingement, rotator cuff syndrome.	
Modified Hawkins-Kennedy for telemedicine	Patient touches top of nonaffected shoulder with hand of affected side while lifting elbow.	Pain may indicate subacromial impingement, rotator cuff syndrome.	
Painful arc test  Sensitivity 53%  Specificity 76% (15)	The patient abducts arms from his sides, with the thumbs pointing up.	Pain from 60°-120° of abduction may indicate subacromial impingement. Pain from 150°-170° of abduction may indicate AC pathology.	
Neer impingement test  Sensitivity 72%  Specificity 60% (15)	Patient holds glass jar of pasta sauce (or equivalent). The patient performs maximal forward flexion of the shoulder with the thumb pointing down.	Anterior shoulder pain with this maneuver may indicate subacromial impingement. Posterior shoulder pain is more indicative on internal impingement.	



Table 2 con't. *Guide to the modified shoulder examination through telemedicine guide.*








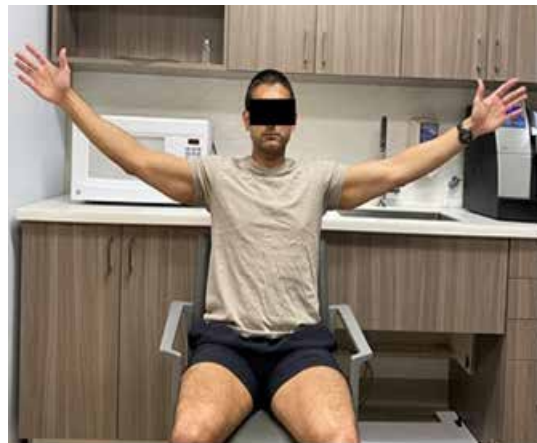	Instruction	Clinical Value	Images
Anterior apprehension test  Sensitivity 72%-98%  Specificity 72%-96% (13)	Typically used for younger patients (under 30 years of age). Have the patient position their shoulder in 90° of abduction and external rotation.	Apprehension or pain in this position may indicate moderate anterior shoulder instability or a possible labral tear.	
Modified anterior apprehension test  Sensitivity 78%  Specificity 75% (19)	Can increase the forces on the anterior capsule if patient places elbow on a solid vertical surface and leans forward 10°-20°.	Apprehension or pain in this position may indicate small anterior shoulder instability or a possible labral tear.	
Cross-body adduction  Sensitivity 77%  Specificity 79% for AC joint pathology (20)	With the shoulder in 90° of elevation and the elbow straight, the patient should reach across their body as far as possible using the contralateral arm to adduct the shoulder.	Pain in the AC joint region with this provocative test may indicate AC pathology.	
Speeds test  Sensitivity 32%  Specificity 61% (16)	With the hand supinated and arm outstretched, raise the arm from the waist while holding a glass, can, or half-filled 2 L bottle of soda.	Pain with this motion may indicate biceps tendon pathology or superior labrum pathology.	

Table 2 con't. *Guide to the modified shoulder examination through telemedicine guide.*

	Instruction	Clinical Value	Images
Strength testing	Using a gallon of milk or similar heavy object, have the patient raise their arm (in the thumbs-up and thumbs-down position).	Weakness or pain may indicate rotator cuff pathology.	 
ROM Tests			
Forward flexion	Elevate arms straight in front of body up above head.	Evaluate for total forward flexion and symmetry. Limitations in flexion may indicate various pathologies, such as impingement, adhesive capsulitis, rotator cuff tears, and others. If active forward flexion is limited, have the patient attempt to perform the motion with assistance from the other hand. This test can rule out adhesive capsulitis.	


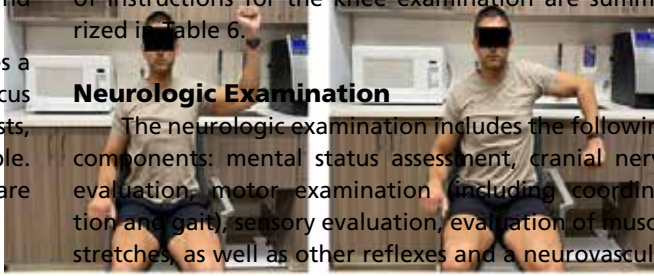


visual and patient-assisted examination skills (21-29). A summary of instructions for the back examination are summarized in Table 4.

## Hip

The hip is a ball-and socket, diarthrodial, synovial joint. Pain originating from the joint is a fairly common complaint of patients presenting to pain clinics. Hip

Table 2 con't. *Guide to the modified shoulder examination through telemedicine guide.*

	Instruction	Clinical Value	Images
Abduction	Elevate arms at sides up above head.	This examination is best observed from behind if possible, to evaluate scapulothoracic motion as the arm externally rotates at 90° of abduction in order for the greater tuberosity to pass under the acromion and continue to full 180° abduction. If active abduction is limited, have the patient attempt to perform the motion with assistance from the other hand. This test can rule out adhesive capsulitis.	
External rotation at side	With the elbow close to the body and in 90° of flexion, the patient externally rotates both arms keeping the elbows tucked close to the body.	Normal external rotation ranges from 45°-90° in this position. Significant loss of external rotation can indicate adhesive capsulitis or glenohumeral arthritis.	
External rotation at side	With the elbow close to the body and in 90° of flexion, the patient externally rotates both arms keeping the elbows tucked close to the body.	Normal external rotation ranges from 45°-90° in this position. Significant loss of external rotation can indicate adhesive capsulitis or glenohumeral arthritis.	

pain, of any pathology, affects approximately 14% of the general population over 60 years of age, and can be caused by a myriad of conditions, including myofascial origin, osteoarthritis, labral tear, femoroacetabular impingement, fracture, sacroiliac joint dysfunction, and greater trochanteric pain syndrome (33). An adequate evaluation of the hip joint involves a thorough history and physical examination, with focus on inspection, ROM, palpation, and provocative tests, and can be further assisted with imaging, if available. A summary of instructions for the hip examination are summarized in Table 5.

examination can assist the physician to diagnose urgent injuries, which necessitate further attention, workup, and possibly surgery, from knee pathologies that can undergo conservative management (35-39). A summary of instructions for the knee examination are summarized in Table 6.


### Neurologic Examination

The neurologic examination includes the following components: mental status assessment, cranial nerve evaluation, motor examination (including coordination and gait), sensory evaluation, evaluation of muscle stretches, as well as other reflexes and a neurovascular assessment. The American Academy of Neurology has recently released a guide to the neurologic examination for telemedicine on its website (41). The guide notes that certain portions of the examination, including the ophthalmologic examination, the vestibular examination, and the evaluation of slight weakness or sensory deficits, may be difficult to perform via telemedicine (41). Upper and lower extremity strength

### Knee

Knee pain is common. The telemedicine knee examination should include a thorough history, inspection, palpation, ROM, and proactive test. There is a spectrum of pathologies causing knee pain, including arthritis, meniscus injury, cruciate and collateral ligament injury, patella instability, osteochondral/fracture injury, and extensor mechanism rupture. The telemedicine knee

Table 3. Guide to the modified hand/wrist/elbow examination through telemedicine guide.

	Visualization/Patient Instructions	Clinical Value	Images
Body Part	Hand/Wrist/Elbow		
Previsit instructions	Ensure the patient has approximately 3 feet free space in all directions.  Video device to be placed 2-3 feet directly in front of patient and propped on a stable surface.	Mobility and position. Patient may be asked to sit and stand to observe balance and sit-stand position transition.	
Physician props	Diagram of hand/wrist/elbow.	Educate patient on hand/wrist/elbow anatomy to describe painful condition once examination is complete.	
Patient props	Mug with large handle, pen/pencil, sheet of paper, jar with lid.	Used for fine and gross muscle motor evaluation.	
Patient clothing	Short sleeves shirt.	Allows inspection to visualize hand, wrist, forearm, and elbow.	
Inspection	Dorsal aspect: inspect wrist, elbow, metacarpophalangeal (MCP), proximal interphalangeal (PIP), and distal interphalangeal (DIP) joints for swelling or erythema. Look for bony deformities including Heberden and Bouchard nodes.  Volar aspect: inspect the thenar muscle at the radial aspect of the palm at the base of the thumb. Inspect the hypothenar muscle at the medial aspect above the wrist.	Swelling and/or erythema at MCPs/PIPs/DIPs may represent synovitis. Swelling of an entire digit may represent dactylitis. Squared appearance at the base of the thumb along with pain may represent CMC arthritis. Swelling at the olecranon may represent olecranon bursitis. Thenar atrophy may represent carpal tunnel syndrome/median neuropathy. Hypothenar muscle atrophy may represent ulnar neuropathy.	

can be assessed as noted earlier. Further motor examination testing can include watching how easily the person pulls him/herself up in bed, how easily he/she can stand up with arms crossed from seated or squatting, observing heel and toe walking, and assessing how well he/she stands on one leg. Additional testing can be considered if there is someone present with the patient being examined. Sensory testing is difficult to complete without another person present but can be attempted. In the tables, the key components of the examination, as well as tips regarding how to perform these components, are. During a telemedicine pain

management assessment, it is anticipated that a relatively focused approach to the neurologic examination will be completed. For example, although all patients might be evaluated for their mental status examination during the telemedicine visit, the pain specialist may be focusing the neurologic assessment on the specific area of complaint. For the patient with low back pain and radicular complaints the examination will likely be focused on the lower extremity; for a person with more widespread complaints it may involve a broader assessment (42-44). A summary of instructions for the neurologic examination are summarized in Table 7.



Table 3 con't. *Guide to the modified hand/wrist/elbow examination through telemedicine guide.*










	Visualization/Patient Instructions	Clinical Value	Images
ROM	Assess finger extension by asking patient to hold hand in front of body, chest height, and spread fingers. Note if DIP, PIP, and MCP joints extend fully. MCP joint extension beyond neutral is normal. Assess finger flexion by observing patient make a fist. Lay palm flat on a table or surface and then flex MCPs, PIPs, and DIPs 90°. To assess grip strength, have patient make a tight fist around a pen. With the opposite hand, have patient try to forcibly remove pen out of gripped hand.	If patient is unable to fully extend MCP joints, it may represent extensor tendon dysfunction.  Inability to perform or maintain full grip may be caused by joint, ligament/tendon, or nerve derangement.	  
Wrist	Have patient turn palms directly upward (90° supination) and downward (90° pronation) while keeping the elbows at sides. With patient's elbows at the side, ask the patient to press the palms together and point fingers upward; then ask the patient to press the back of the hands together and point the fingers downward.	Difficulty in wrist pronation/supination may reflect instability of the distal radioulnar joint, carpal ligaments, forearm fracture, and/or elbow impairment.  Wrists should extend and flex approximately to 90°.	   
Elbow	Full flexion and extension should be without pain. Pain with flexion and extension may reflect underlying synovitis.	Pain with flexion and extension may reflect underlying synovitis.	 



Table 3 con't. *Guide to the modified hand/wrist/elbow examination through telemedicine guide.*



	Visualization/Patient Instructions	Clinical Value	Images
<p>Trigger finger (hand)</p> <p>Specificity 95%</p> <p>Sensitivity 66%</p>	<p>Grabbing and releasing large handle of a mug with digits 2-5.</p>	<p>Reproduces pressure at the volar aspect of the MCPs and produces finger flexion. Subsequent extension with pain and “triggering” of a digit after removing the digits from the handle may represent a trigger finger. The superficialis tendons extend to the base of the middle phalanx and the flexor profundus tendons extend to the base of the distal phalanx of each finger. If the patient experiences tenderness with pressure and a popping sensation or locking of a digit on flexion (digits around mug handle) with pain and clicking on subsequent extension (releasing digits from the handle), it may suggest a trigger finger.</p>	
<p>De Quervain tenosynovitis: Finkelstein test (wrist)</p> <p>Sensitivity 99%</p> <p>Specificity 29% (17)</p>	<p>Have patient flex and abduct thumb across palm, and then flex fingers around the thumb. Have patient bend wrist toward the fifth digit (ulnar deviation).</p>	<p>Pain with this maneuver may suggest tendonitis of abductor pollicis longus and extensor brevis. Patients may also have tenderness to palpation and swelling on inspection of region at radial styloid.</p>	

Table 3 con't. *Guide to the modified hand/wrist/elbow examination through telemedicine guide.*





	Visualization/Patient Instructions	Clinical Value	Images
Lateral epicondylitis: Mill test (elbow)  Sensitivity 53%  Specificity 100% (18)	Have patient extend pronated arm straight in front with wrist in flexion. With opposite hand, grip the fingers of the flexed wrist and pull downward.	A stretch should be felt in the dorsal aspect of forearm and pain may be elicited at the area of the lateral epicondyle. Patient may have pain on palpation at the lateral epicondyle.	
Medial epicondylitis: Reverse Mill test (elbow)	Have patient extend arm straight in front (palm up) with wrist in extension. With opposite hand, grip the fingers of the extended wrist and pull back.	A stretch should be felt in the volar aspect of forearm and pain may be elicited at the area of the medial epicondyle. Patient may have pain on palpation at medial epicondyle.	
Degenerative Joint Disease			
First CMC joint	Have patient pinch a piece of paper in-between thumb and second digit. With opposite hand try to remove paper with a significant "tug." Repeat using thumb and third digit.	Pain at base of thumb with CMC arthritis.	
First CMC joint	Have patient try to twist open lid of an unopened jar.	Patient will have pain at base of thumb with CMC arthritis.	

Table 4. Guide to the modified lumbar spine examination through telemedicine guide.




	Instruction	Clinical Value	Images
Body Part	Back Examination		
Previsit instructions	<p>Ensure the patient has approximately 6 feet free space in all directions.</p> <p>Video device to be placed 6 feet directly in front of patient and propped on a stable surface.</p> <p>Position the device to be able to visualize from head to toe.</p>	<p>Mobility and position. Patient may be asked to sit and stand to observe balance and sit-stand position transition.</p>	
Physician props	Spine model.	Educate patient on lumbar anatomy to describe painful condition once examination is complete.	
Patient props	<p>Chair, bed, or couch.</p> <p>Q-tip for light touch testing.</p> <p>Wooden spoon.</p>	<p>Assess position changes.</p> <p>Point to painful area(s).</p>	
Patient clothing	Shorts and t-shirt.	Allow easy visualization of examination areas.	
Activity	Instructions	Clinical Value	
General appearance	Patient to stand naturally in front of camera.	<p>Asymmetry during standing suggests limb or lumbar pathology.</p> <p>Patients with SIJ pain may offload painful side.</p>	
Gait	Instruct patient to walk toward or away from the camera and turn around and walk back.	<p>Gait assessment.</p> <p>Antalgia suggests painful hip, knee, ankle, foot.</p> <p>Increased hip rise may mean that patient is unable to clear the floor normally with foot.</p> <p>Consider weak dorsiflexors as explanation.</p> <p>Cross-reference with heel walk suggests (L4) nerve root pathology (24).</p>	

Table 4 con't. *Guide to the modified lumbar spine examination through telemedicine guide.*

	Instruction	Clinical Value	Images
Muscle strength	Instruct patient to walk on their heels.	Poor/no heel walk. Weak ankle dorsiflexors: TA, EDL, EHL (L4)  Heel walk is also a recognized test for proprioception (25).	
	Instruct patient to walk on their toes.	Poor/no toe walk suggests weak ankle plantar flexors: gastrosoleus (S1, S2).	

## DISCUSSION

Telemedicine requires the clinician to greatly focus on observation skills. Ironically, medicine has lost much of this emphasis in contrast to how it was taught and practiced centuries ago. According to Sir William Osler's own words, "The student starts . . . as an observer of ....structure and orderly functions of which he is perfectly familiar. Teach him how to observe....The whole art of medicine is in observation" (41).

The explosive growth of telemedicine will require providers to use their clinical skills in a novel venue.

A conscientious history and physical examination are essential for patient diagnosis and management. The most meaningful aspects of this evaluative process can be performed through an audio/video format.

The history of the chief complaint, along with the past medical and functional history, provides the most necessary information but the physical examination remains an important screening tool to improve diagnostic accuracy, even when limited to those static, dynamic, and provoked signs of a patient's pathology that can be observed through a camera (45). Estimates

Table 4 con't. *Guide to the modified lumbar spine examination through telemedicine guide.*


	Instruction	Clinical Value	Images
	Instruct patient to stand on one leg.	Pelvis on unsupported leg does not elevate, consider gluteus medius weakness (L5). Positive Trendelenburg test.	
Inspection Validated tool	Ask patient to stand comfortably 6 feet from camera.	<p>Asymmetrically high pelvis on one side and ipsilateral shoulder drop suggests advanced degenerative spondylosis due to scoliosis. Consider lumbar facet test for confirmation of pain generator.</p> <p>Muscle bulk and symmetry: paraspinals, thigh, leg wasting/asymmetry. Muscle atrophy; neuropathy</p> <p>Using a wooden spoon, point to area that is usually the most painful point at PSIS suggests SIJ pathology (Fortin finger test)</p>	



Table 4 con't. *Guide to the modified lumbar spine examination through telemedicine guide.*



	Instruction	Clinical Value	Images
Posture	Advise that patient stand sideways in relation to the video camera.	<p>Pronounced kyphosis suggests old compression fractures. Spondylolisthesis.</p> <p>Pronounced lumbar lordosis suggests muscle imbalances: weak abdominal muscles, tight or weak iliopsoas, hamstrings.</p> <p>Hip flexion with forward inclined trunk, flat back sway back posture.</p>	
ROM	Instruct the patient to turn and touch their toes.	<p>Pain radiates into lower limb/s w/ flexion suggests HNP, discogenic pain, paraspinous spasm. Pain without radiation may suggest inflammatory arthritis, Spondylosis.</p>	
ROM	Instruct the patient to extend their spine.	<p>Extension and referred pain into lower limb/s w/ extension suggests central canal stenosis, HNP/nerve root irritation. Pain without radiation suggests facet pathology.</p>	

Table 4 con't. *Guide to the modified lumbar spine examination through telemedicine guide.*






	Instruction	Clinical Value	Images
ROM	Instruct patient to side bend to left and right side.	Radiating leg pain suggests neuroforaminal stenosis.	 
Hip ROM	Instruct the patient to cross one thigh over the other (always test hip ROM with back examination).	Limited hip flexion and internal rotation with groin pain. Suspect hip pathology causing lumbar pain.	

Table 4 con't. *Guide to the modified lumbar spine examination through telemedicine guide.*



	Instruction	Clinical Value	Images
Palpation	Instruct patient to press hand over lumbar area corresponding to spine, quadratus lumborum, and periliac crest areas.	Tenderness at lumbar spinous process, sacrum, facet/SIJ/paraspinal or gluteal, piriformis muscles, greater trochanters.  Reproducible lumbar pain with palpation may suggest episacral fat pad as cause of symptoms.	
Sitting Maneuvers			
Slump test  Sensitivity 84%  Specificity 83% (26)	Advise patient to place hands behind back, then perform chin to chest tuck and lean forward, straighten out right leg. Repeat with left side.	Positive slump test: reproducible and radiating low back and lower limb pain suggests HNP/nerve root irritation.	

about the need for an in-person physical examination to reach a definitive diagnosis range between 10% and 15%. Laboratory investigations, as easily guided from a telemedicine platform as from an office visit, contribute to a diagnosis at about the same rate and in many instances only confirm or exclude a diagnosis. The physical examination can also exclude diagnostic possibilities and increase diagnostic confidence (46). Seventy percent of clinicians worldwide feel that the physical examination is almost always valuable. The same study, however, reveals that approximately 85% of clinicians feel that physical examination of the joints, and in particular of the knee, is only valuable 30% to 40% of the time (47). The largest part of the physical examination

is observation, with notable exceptions for diagnoses requiring auscultation (heart, lungs, abdomen) and expert palpation (abdomen, genitourinary system).

Observation is an important tool in making a diagnosis, assessing symptoms, and monitoring progress. General observation of posture and movement is best augmented by specific focal observations that target examination abnormalities. Observation of the patient and their environment yields a wealth of diagnostic examination detail. Speech, gestures, transitional movements, gait, and manipulation of objects reflect the status of the neurologic and musculoskeletal systems. Other more constitutional findings, such as cyanosis, jaundice, pallor, diaphoresis, blanching, or flushing can

Table 4 con't. *Guide to the modified lumbar spine examination through telemedicine guide.*

	Instruction	Clinical Value	Images
Muscle strength	Instruct patient to raise right knee off the chair or bed.	<p>Hip flexor strength L2/L3 radiculopathy or iliopsoas weakness.</p> <p>Inability to keep thigh up for 60 seconds suggests hip flexor weakness (23,30).</p> <p>Ability to rise from chair without using arms for assistance suggests normal hip flexor, knee extensor, and hip extensor strength.</p>	
Straight leg raise test Sensitivity 95% Specificity 95% Crossed straight leg raise test Sensitivity 95% Specificity 95%	Instruct patient to extend leg while sitting in chair.	<p>Knee extensor strength L3/4 radiculopathy or weak quadriceps.</p> <p>Radiating posterior thigh pain may be due to tight hamstring or HNP.</p> <p>If nonpainful leg raise causes ipsilateral symptoms more strongly suggestive of radiculitis (crossed straight leg raise) (27-29).</p>	

be evidence of disease in other systems. Visible personal objects and condition of their surroundings might provide insight into a patient's personality.


Symptom evaluation is typically a function of the history, but symptoms can also be assessed observationally in a standardized, validated format. One example of this is the BOS-3 (Behavioral Observation Scale 3) to assess pain. It grades verbal or nonverbal patients for specific facies, antalgic or analgesic postures and movements, and other observed pain behaviors.

A competent observer needs to recognize both the technical and personal limitations of the observed telemedicine examination. Many physical findings have a high degree of interobserver variability and should be deemphasized in favor of those with better repro-

ducibility. Asymmetry remains an invaluable clue in the video examination (46). Patients should be observed while sitting, standing, transitioning, and walking. Scan the patient in an organized manner. Atrophy/contour, posture/movement, and symmetry of the neck, trunk, pelvis, and extremities informs the subsequent examination.

In quiet stance, a patient should display no visible postural sway. The line of gravity should be anterior to the hips, behind the knees, and just in front of the ankle. There are multiple causes of visible postural sway but alteration in the line of gravity typically reflects a musculoskeletal derangement—either of skeletal misalignment or muscle/tendon tightness or contracture. Lumbar, thoracic, and cervical curves can be grossly

Table 4 con't. *Guide to the modified lumbar spine examination through telemedicine guide.*

	Instruction	Clinical Value	Images
Seated FABER test Sensitivity 41% Specificity 100% (31)	Instruct patient to cross leg and place ankle on opposite knee then push the bent knee down with your hand.	Ipsilateral buttock pain suspicious for SIJ pathology.	 A photograph of a male patient sitting on a chair, performing the Seated FABER test. He is crossing his right leg over his left knee and pushing down on his right knee with his right hand. A red arrow points to the right buttock area, indicating the location of potential pain.
Seated Valsalva	Instruct patient to perform Valsalva while seated and in truncal flexed position.	Suggests HNP, but also may rule out abdominal visceral pathology as source of referred pain to lumbar region (32).	



EDL, extensor digitorum longus; EHL, extensor hallucis longus; HNP, herniated nucleus pulposus; PSIS, posterior superior iliac spine; SIJ, sacroiliac joint; TA, tibialis anterior.

Table 5. *Guide to the modified hip examination through telemedicine guide.*

	Instruction	Clinical Value	Images
Body Part	Hip Examination		
Physician props	Diagram of hip anatomy.	Educate patient on hip anatomy to describe painful condition once examination is complete.	
Patient props	Chair and table.	Chair will allow patient to perform ROM and provocative maneuvers. Table for balance during examination.	
Patient clothing and prep	Shorts allows visualization of painful area.  Leggings/yoga pants, nonrestrictive and allow ROM assessment.  Ensure patient has approximately 6 feet of space in all directions and able to position on the chair, and away from the camera.	Allow visualization of examination of torso and trunk.	



Table 5 con't. *Guide to the modified hip examination through telemedicine guide.*

	Instruction	Clinical Value	Images
Single leg sit stand	<p>Instruct patient to stand up using the strength of one leg.</p> <p>The contralateral hand is used for balance.</p>	Weakness could suggest gluteus medius weakness or L5 radiculopathy.	 
Raise your knee	Advise to lift thigh and push the knee down with hands.	Suggests hip flexor strength, L2 radicular pathology, or iliopsoas tendinopathy.	
Hip ROM	Instruct the patient to cross one thigh over the other (always test hip ROM with back examination).	<p>Limited hip flexion and internal rotation with groin pain.</p> <p>Suspect hip pathology.</p>	

assessed by having the patient stand with their back against the wall, and any gapping between the occiput and wall or low back and wall noted. Bringing the shoulders to the wall gives a sense of shoulder protraction, whereas the gap between the wall and feet may

suggest hamstring tightness. Looking at the patient from a lateral view will supplement information on spinal alignment and any restriction of muscles around the hips. Viewing the patient from behind might suggest a leg length discrepancy, as well as a scoliosis. Restricted

Table 5 con't. *Guide to the modified hip examination through telemedicine guide.*



	Instruction	Clinical Value	Images
Seated FABER  Sensitivity 41% Specificity 100% (31)	Cross leg putting your right ankle on your left knee. Now push your right knee toward the ground. Any pain?	Pain: piriformis pain or sacroiliac joint pathology.	
Trochanter palpation	Palpate lateral hip for tenderness.	Suggests greater trochanteric bursitis.	
FADIR (flexion, adduction, and internal rotation)  Sensitivity 41%  Specificity 47% (34)	<p>Patient places the foot of the leg to be evaluated onto a chair while stabilizing balance using their ipsilateral hand on the chair back.</p> <p>Both knee and hip are placed in a flexed posture.</p> <p>Contralateral hand draws the knee across the midline, resulting in relative adduction and internal rotation of the hip joint with the joint in flexion.</p>	Patients with symptomatic hip articular pathology will often experience reproduction of their typical midinguinal groin pain at this stage (positive test).	

Table 6. *Guide to the modified knee examination through telemedicine guide.*



Body Part	Knee Examination	Clinical Value	Images
Previsit instructions	Ensure patient has a minimum of 6 feet of space around them to position yourself to stand and sit at a chair, move from side to side and forward and backward. Position camera 6 feet away so physician can see both knees and thigh up to mid orso.	Mobility and position. Patient may be asked to sit and stand to observe balance and sit-stand position transition.	
Physician props	Knee model or diagram.	Educate patient on neck anatomy to describe painful condition once examination is complete.	
Patient props	2 chairs for use with examination.	Maneuverability and balance during examination.	
Patient clothing	Dressed in shorts that end above the knee. May need to be rolled up for visualization of quadriceps muscle.	Allow visualization of examination areas.	
Inspection	Instruct patient to stand in front of chair with legs close together for comparison.	Compare for effusion, abrasions, bruising, ecchymosis, muscle atrophy, patella alta and baja, patella subluxation/dislocation. Assess for unilateral lower extremity edema and erythema to rule out potential deep venous thrombosis. COVID infection and/or lack of activity due to pain may induce coagulopathy (2).	
Gait	Have patient walk back and forth in front of camera.	Assess gait pattern: antalgic, hip rise, stance phase, heel rise, swing phase, heel rise, and toe touch.	
Palpation	Have patient point to area of tenderness or maximal pain.	Helps confirm patient's description of pain area.	

Table 6 con't. *Guide to the modified knee examination through telemedicine guide.*

Body Part	Knee Examination	Clinical Value	Images
Active straight leg raise	Instruct patient sit on one chair with legs on another chair close together.  Have patient do straight leg raise.	Checks for extensor mechanism to evaluate for quadriceps or patella tendon rupture.	
Quadriceps contraction	Instruct patient sit on chair and contract quadriceps.	Checks for flexion contracture/inability to fully extend for possible intraarticular pathology (meniscus, osteochondral defect, cruciate injury, hamstring tightness).	
ROM	While still sitting with both legs on other chair have patient flex affected knee then contralateral knee for comparison.	ROM with assessment of pain.	

motion, atrophy or asymmetry of neck and shoulder posture, or reach when seated at rest can reflect muscle spasm or radiculopathy with related pain and should prompt more targeted observation for these diagnoses.

Does the patient need to supplement lower extremity strength or balance by use of their upper extremities when rising to stand? Is there an antalgic avoidance of heel strike as with advanced osteoarthritis? Does a foot slap indicate dorsiflexor weakness? A focused neuromusculoskeletal video examination should follow such findings. Expertly conducted, the clinical value of a video remote examination should have a value almost equivalent to that of an in-office assessment.

Academic pain centers (APCs), like most other medical practices, have been significantly affected by state and national orders to limit office visits and elective procedures. Many practices have truncated their services offered to telemedical visits and emergency visits only; some have completely closed. Although video encounters billing as E/M visits has helped maintain at least a portion of revenue and productivity,

the pandemic has had devastating financial effects on many medical practices including APCs (48). Even now, as social distancing orders are starting to be lifted, it is unlikely that pain patients will be in a rush to return for both office visits and elective procedures until there is a reliable treatment or a vaccine for COVID-19. Two of the multiple reasons for this are that most pain patients are elderly and suffer from many comorbidities making them more susceptible, and there is some evidence that steroid injections are associated with increased viral pneumonia risk (49). Therefore telemedicine, and specifically video encounters, will remain our primary interaction with our patients into the foreseeable future.

In this unique and timely investigation, our group of experts has presented focused physical examination principles of the neck, shoulder, elbow/wrist/hand, back, hip, and knee that can be performed outside of the clinical setting and without physical clinician intervention. Our group has modified some examinations from their validated counterparts in order that they can be performed passively. Although our group does

Table 6 con't. *Guide to the modified knee examination through telemedicine guide.*



Body Part	Knee Examination	Clinical Value	Images
Patella palpation	While sitting have patient palpate medial and lateral patella facets, inferior pole and superior pole of patella.	Assessment for chondromalacia patella, patella tendinopathy, and quadriceps tendinopathy.	
Single leg stance	Instruct the patient to stand. Then have patient single leg stance on affected side, then nonaffected side. Have patient move from side to side (36,37).	If no pain, with good motion and balance, this test can effectively rule out anterior cruciate ligament, meniscus injury, fracture, patella dislocation, and osteochondral injury.	



Table 6 con't. *Guide to the modified knee examination through telemedicine guide.*




Body Part	Knee Examination	Clinical Value	Images
<p>Varus/valgus test</p> <p>Valgus sensitivity 86%-96%; specificity not reported (38)</p> <p>Varus sensitivity 25%; specificity not reported (38)</p>	<p>Instruct patient to sit on chair. Foot of affected knee firmly planted on floor with knee flexed 20°-30°. Have patient apply a varus load with hand to knee and then a valgus load.</p>	<p>Collateral ligament injury.</p> <p>Patients with suspected medial collateral ligament or lateral collateral ligament injury may have pain with joint opening with manual stress.</p>	
<p>Thessaly test</p> <p>Sensitivity 62%</p> <p>Specificity 55% (39)</p>	<p>Have the patient hold on the back of the chair with both hands while standing flatfooted on the floor. The patient then rotates his or her knee and body, internally and externally, 3 times, keeping the knee in slight flexion of 20°.</p>	<p>Meniscus injury.</p> <p>Patients with a suspected meniscal tear will experience medial or lateral joint line pain if the test is positive.</p>	

Table 6 con't. *Guide to the modified knee examination through telemedicine guide.*

Body Part	Knee Examination	Clinical Value	Images
Patella apprehension test  Sensitivity 100%  Specificity 88% (40)	With patient sitting down have patient put laterally directed stress on patella from medial side.	Assessment for patella instability. Test will show apprehension and pain.	

not believe that our intervention devalues them, we do submit that further studies may be required to validate these recommendations for telemedicine use.

## CONCLUSIONS

Pain is the most common complaint in the clinical setting, and, related to the current pandemic, dramatic changes in how health care is delivered is currently taking place. Telemedicine in pain management is now a necessity and requires methodical appreciation for the limits of this venue in assessment of pain states. In this regard, the physical examination is an essential component for sound clinical judgment and patient care planning. The physical examinations described in this investigation provide a comprehensive framework for the musculoskeletal and neurologic examination, which has been vetted by a committee of national experts for incorporation into the telemedicine evaluation.

## Author Contributions

All the authors were involved in the conception, data collection, analysis, writing and revision of this article.

Dr. Wahezi is Associate Professor of Physical Medicine and Rehabilitation, Anesthesiology, and Orthopedic Surgery at Albert Einstein College of Medicine, Program Director of the Montefiore Multidisciplinary Pain Fellowship, Bronx, NY.

swahezi@montefiore.org

Dr. Duarte is Director of the Pain Center at North-

well Health, Great Neck, NY; and Assistant Professor of Neurology at Hofstra North Shore-LIJ School of Medicine, Manhasset, NY.

RDuarte@northwell.edu

Dr. Yerra is Clinical Research Fellow at Physical Medicine and Rehabilitation at Montefiore Medical Center, Bronx, NY.

Drsandeepyerra@gmail.com

Dr. Thomas is Associate Professor of Physical Medicine and Rehabilitation at Albert Einstein College of Medicine, Bronx, NY; and Residency Training Program Director of Physical Medicine and Rehabilitation at Montefiore Medical Center, Bronx, NY.

mathomas@montefiore.org

Dr. Pujar is Clinical Research Coordinator at Montefiore Medical Center, Bronx, NY.

bpujar@montefiore.org

Dr. Sehgal is Chair Division of Rehabilitation Medicine, Vice Chair Department of Orthopedics & Rehabilitation, University of Wisconsin School of Medicine & Public Health, and Program Director, Pain Medicine (Multidisciplinary) Fellowship Program, University of Wisconsin, UW Health, Madison, WI.

Sehgal@rehab.wisc.edu

Dr. Gonzalez is Director of Orthopedic Sports Medicine at Montefiore Medical Center, Bronx, NY; and Assistant Professor of Orthopedic Surgery at Albert Einstein College of Medicine, Bronx, NY.

dgonzale@montefiore.org

Dr. Kim is Professor in Department of Physical Med-

icine and Rehabilitation and Anesthesiology at Case Western Reserve University, Cleveland, OH; Program Director of the Pain Medicine Fellowship at Case Western Reserve University/MetroHealth, Cleveland, OH; Director of the Musculoskeletal Rehabilitation Division in the Department of Physical Medicine and Rehabilitation at MetroHealth Medical Center, Cleveland, OH; Director of Pain and Healing Center at MetroHealth Medical Center, Cleveland, OH; and Co-Director of the Spine Center at MetroHealth Medical Center, Cleveland, OH.

Ckim3@metrohealth.org

Dr. Ruchi Jain is Assistant Professor of Medicine, Rheumatology Division at Albert Einstein College of Medicine and Montefiore Medical Center, Bronx, NY.

ruchjain@montefiore.org

Dr. Hossack is Director of Cartilage Restoration Surgery at Montefiore Medical Center, Professor of Orthopedic Surgery at Albert Einstein College of Medicine, Bronx, NY.

mihossac@montefiore.org

Dr. Senthelal is a Fellow in the Multidisciplinary Pain Program Center at Montefiore Medical Center/Albert Einstein College of Medicine, Bronx, NY.

ssenthel@montefiore.org

Dr. Ankush Jain is a Fellow in the Multidisciplinary Pain Program Center at Montefiore Medical Center/Albert Einstein College of Medicine, Bronx, NY.

anjain@montefiore.org

Dr. Leo is a Fellow in the Multidisciplinary Pain Program Center at Montefiore Medical Center/Albert Einstein College of Medicine, Bronx, NY.

nleo@montefiore.org

Dr. Shaparin is Associate Professor in Department of Anesthesiology and Physical Medicine and Rehabilitation at Albert Einstein College of Medicine, Bronx, NY; Associate Professor of Family and Social Medicine at Albert Einstein College of Medicine, Bronx, NY; and Director of Pain Services at Montefiore Medical Center, Bronx, NY.

nshapari@montefiore.org

Dr. Argoff is Assistant Professor of Neurology at Albany Medical College, Albany, NY; and Director of the Comprehensive Pain Program at Albany Medical Center, Albany, NY.

cargoff@nycap.rr.com

Dr. Daniel Wong is a Fellow in the Multidisciplinary

Pain Program Center at Montefiore Medical Center/Albert Einstein College of Medicine, Bronx, NY.

danwong@montefiore.org

Dr. Ashley Wong is a Fellow in the Multidisciplinary Pain Program Center at Montefiore Medical Center/Albert Einstein College of Medicine, Bronx, NY.

aswong@montefiore.org

Dr. Nguyen is a Fellow in the Multidisciplinary Pain Program Center at Montefiore Medical Center/Albert Einstein College of Medicine, Bronx, NY.

kinguyen@montefiore.org

Dr. Manchikanti is Co-Director, Pain Management Centers of America, Paducah, KY; Clinical Professor, Anesthesiology and Perioperative Medicine, University of Louisville, Louisville, KY; and Professor of Anesthesiology-Research, Department of Anesthesiology, School of Medicine, LSU Health Sciences Center, New Orleans, LA.

drlm@thepainmd.com

Dr. Singh is Vice Chair and Associate Professor in the Department of Rehabilitation Medicine at Weil Cornell Medicine, New York, NY; and Adjunct Associate Professor of Rehabilitation and Regenerative Medicine at Columbia University College of Physicians and Surgeons, New York, NY.

jrs9012@med.cornell.edu

Dr. Grieco is Associate Professor of Neurology at North Shore-LIJ Medical Center, New Hyde Park, NY.

ggrieco@northwell.edu

Dr. Patel is a Neurology Resident Physician at North Shore-LIJ Medical Center, New Hyde Park, NY.

apatel40@northwell.edu

Dr. Merritt D. Kinon is Assistant Professor of Neurosurgery and Director of Spinal Surgery Education at Montefiore Medical Center/Albert Einstein College of Medicine, Bronx, NY.

mkinon@montefiore.org

Dr. Kaye is Vice-Chancellor of Academic Affairs, Chief Academic Officer, and Provost, Professor of Anesthesiology and Pharmacology, Toxicology, and Neurosciences, Louisiana State University Health Sciences Center, School of Medicine, Shreveport, LA; Professor of Anesthesiology and Pharmacology, LSU School of Medicine, New Orleans, LA; and Professor of Anesthesiology and Pharmacology, Tulane School of Medicine, New Orleans, LA.

akaye@lsuhsc.edu, alankaye44@hotmail.com

## REFERENCES

- COVID-19 dashboard by the Center for Systems Science and Engineering (CSSE) at Johns Hopkins University (JHU). ArcGIS. Available at: <https://gisanddata.maps.arcgis.com/apps/opsdashboard/index.html#/bda7594740fd40299423467b48e9ecf6>. Accessed May 28, 2020.
- Grimm CA. US Department of Health and Human Services. Office of Inspector General. Hospital experiences responding to the COVID-19 pandemic: Results of a National Pulse Survey March 23-27, 2020. April 2020, OEI-06-20-00300. Available at: <https://oig.hhs.gov/oei/reports/oei-06-20-00300.asp>. Accessed May 28, 2020.
- Kohan L, Sobey C, Wahezi S, et al. Maintaining high quality multidisciplinary pain medicine fellowship programs: Part II: Innovations in clinical care workflow, clinical supervision, job satisfaction and postgraduation mentorship for pain fellows during the Covid-19 pandemic. *Pain Med* 2020 June 10. [Epub ahead of print].
- Murray CJ, Atkinson C, Bhalla K, et al; U.S. Burden of Disease Collaborators. The state of US health, 1990-2010: Burden of diseases, injuries, and risk factors. *JAMA* 2013; 310:591-608.
- Fejer R, Kyvik KO, Hartvigsen J. The prevalence of neck pain in the world population: A systematic critical review of the literature. *Eur Spine J* 2005; 15:834-848.
- Hogg-Johnson S, van der Velde G, Carroll LJ, et al. The burden and determinants of neck pain in the general population. *Spine (Phila Pa 1976)* 2008; 33:S39-S51.
- Binder AI. Neck pain. *BMJ Clin Evid* 2008; 2008:1103.
- Fernández-De-Las-Peñas C, Hernández-Barrera V, Alonso-Blanco C, et al. Prevalence of neck and low back pain in community-dwelling adults in Spain: A population-based national study. *Spine (Phila Pa 1976)* 2011; 36:E213-E219.
- Wainner RS, Fritz JM, Irrgang JJ, et al. Reliability and diagnostic accuracy of the clinical examination and patient self-report measures for cervical radiculopathy. *Spine* 2003; 28:52-62.
- Cohen SP. Epidemiology, diagnosis, and treatment of neck pain. *Mayo Clin Proc* 2015; 90:284-299.
- Khare S, Seth D. Lhermitte's sign: The current status. *Ann Indian Acad Neurol* 2015; 18:154-156.
- Tong HC, Haig AJ, Yamakawa K. The Spurling test and cervical radiculopathy. *Spine (Phila Pa 1976)* 2002; 27:156-159.
- Hippensteel KJ, Brophy R, Smith MV, Wright RW. Comprehensive review of provocative and instability physical examination tests of the shoulder. *J Am Acad Orthop Surg* 2019; 27:395-404.
- Cotter EJ, Hannon CP, Christian D, Frank RM, Bach Jr BR. Comprehensive examination of the athlete's shoulder. *Sports Health* 2018; 10:366-375.
- Hegedus EJ, Goode AP, Cook CE, et al. Which physical examination tests provide clinicians with the most value when examining the shoulder? Update of a systematic review with meta-analysis of individual tests. *Br J Sports Med* 2012; 46:964-978.
- Hegedus EJ, Goode A, Campbell S, et al. Physical examination tests of the shoulder: A systematic review with meta-analysis of individual tests. *Br J Sports Med* 2008; 42:80-92.
- Goubau JF, Goubau L, Van Tongel A, Van Hoonacker P, Kerckhove D, Berghs B. The wrist hyperflexion and abduction of the thumb (WHAT) test: A more specific and sensitive test to diagnose de Quervain tenosynovitis than the Eichhoff's Test. *J Hand Surg Eur Vol* 2014; 39:286-292.
- Saroja G, Aseer AL, Sai V. Diagnostic accuracy of provocative tests in lateral epicondylitis. *Int J Physio Res* 2014; 2:815-823.
- Geraci Jr MC, Allea JT. The physical examination of the spine and its functional kinetic chain. In: Cole AJ, Herring SA (eds). *The Low Back Pain Handbook: A Practical Guide for the Primary Care Clinician*. Philadelphia, Hanley & Belfus, 1997: pp. 69-93.
- Chronopoulos E, Kim TK, Park HB, Ashenbrenner D, McFarland EG. Diagnostic value of physical tests for isolated chronic acromioclavicular lesions. *Am J Sports Med* 2004; 32:655-661.
- Bogduk N. *Clinical Anatomy of the Lumbar Spine and Sacrum*, 4th ed. London, Churchill Livingstone, 2005.
- Frontera WR, DeLisa JA, Gans BM, Robinson LR, Bockenek W, Chae J. DeLisa's Physical Medicine and Rehabilitation: Principles and Practice, 6th ed. Philadelphia, Wolters Kluwer, 2019.
- Scholten P, Chekka K, Benzon HT. Physical examination of the patient with pain. In: Benzon HT, Raja SN, Fishman SM, Liu SS, Cohen SP (eds). *Essentials of Pain Medicine*, 4th ed. New York, Elsevier, 2018: pp. 27-38.
- Cuccurullo S. *Physical Medicine and Rehabilitation Board Review*, 4th ed. New York, Demos Medical, 2019.
- Reeves AG, Swenson RS. Disorders of the Nervous System. Evaluation of the patient with "numbness." Dartmouth Medical School. Available at: [www.dartmouth.edu/~dons/part\\_2/chapter\\_13.html](http://www.dartmouth.edu/~dons/part_2/chapter_13.html). Accessed July 23, 2020.
- Majlesi J, Togay H, Unalan H, Toprak S. The sensitivity and specificity of the slump and the straight leg raising tests in patients with lumbar disc herniation. *J Clin Rheumatol* 2008; 14:87-91.
- Tawa N, Rhoda A, Diener I. Accuracy of clinical neurological examination in diagnosing lumbo-sacral radiculopathy: A systematic literature review. *BMC Musculoskelet Disord* 2017; 18:93.
- Van der Windt DA, Simons E, Riphagen II, et al. Physical examination for lumbar radiculopathy due to disc herniation in patients with low-back pain. *Cochrane Database Syst Rev* 2010; 2:CD007431.
- Telli H, Telli S, Topal M. The validity and reliability of provocation tests in the diagnosis of sacroiliac joint dysfunction. *Pain Physician* 2018; 21:E367-E376.
- Huber AM, Feldman BM, Rennebohm RM, et al. Validation and clinical significance of the Childhood Myositis Assessment Scale for assessment of muscle function in the juvenile idiopathic inflammatory myopathies. *Arthritis Rheum* 2004; 50:1595-1603.
- Troelsen A, Mechlenburg I, Gelineck J, Bolvig L, Jacobsen S, Søballe K. What is the role of clinical tests and ultrasound in acetabular labral tear diagnostics? *Acta Orthop* 2009; 80:314-318.
- Goldish GD, Quast JE, Blow JJ, Kuskowski MA. Postural effects on intra-abdominal pressure during Valsalva maneuver. *Arch Phys Med Rehabil* 1994; 75:324-327.
- Christmas C, Crespo CJ, Franckowiak SC, Bathon JM, Bartlett SJ, Andersen RE.

- How common is hip pain among older adults? Results from the Third National Health and Nutrition Examination Survey. *J Fam Pract* 2002; 51:345-348.
34. Casartelli NC, Brunner R, Maffiuletti NA, et al. The FADIR test accuracy for screening cam and pincer morphology in youth ice hockey players. *J Sci Med Sport* 2018; 21:134-138.
35. Nguyen US, Zhang Y, Zhu Y, Niu J, Zhang B, Felson DT. Increasing prevalence of knee pain and symptomatic knee osteoarthritis: Survey and cohort data. *Ann Intern Med* 2011; 155:725-732.
36. Lehmann T, Paschen L, Baumeister J. Single-leg assessment of postural stability after anterior cruciate ligament injury: A systematic review and meta-analysis. *Sports Med Open* 2017; 3:32.
37. Negahban H, Mazaheri M, Kingma I, van Dieën JH. A systematic review of postural control during single-leg stance in patients with untreated anterior cruciate ligament injury. *Knee Surg Sports Traumatol Arthrosc* 2014; 22:1491-1504.
38. Malanga GA, Andrus S, Nadler SF, McLean J. Physical examination of the knee: A review of the original test description and scientific validity of common orthopedic tests. *Arch Phys Med Rehabil* 2003; 84:592-603.
39. Konan S, Rayan F, Haddad FS. Do physical diagnostic tests accurately detect meniscal tears? *Knee Surg Sports Traumatol Arthrosc* 2009; 17:806-811.
40. Ahmad CS, McCarthy M, Gomez JA, Shubin Stein BE. The moving patellar apprehension test for lateral patellar instability. *Am J Sports Med* 2009; 37:791-796.
41. AAN Publications. NeuroBytes: The neurologic exam via telemedicine. Available at: <https://learning.aan.com/diweb/catalog/item/id/5033281>. Accessed May 28, 2020.
42. Lyden P. Using the National Institutes of Health Stroke Scale: A cautionary tale. *Stroke* 2017; 48:513-519.
43. Kumar SP, Ramasubramanian D. The Babinski sign--A reappraisal. *Neurol India* 2000; 48:314-318.
44. Haddox, JD. Pain-focused mental status examination. *Curr Rev Pain* 1999; 3:42-47.
45. Saleem SM, Pasquale LR, Sidoti PA, Tsai JC. Virtual ophthalmology: Telemedicine in a Covid-19 era. *Am J Ophthalmol* 2020 Apr 30. [Epub ahead of print].
46. Mills S, Nicolson KP, Smith BH. Chronic pain: A review of its epidemiology and associated factors in population-based studies. *Br J Anaesth* 2019; 123:e273-e283.
47. Yengo-Kahn AM, Hale AT, Zalneraitis BH, Zuckerman SL, Sills AK, Solomon GS. The Sport Concussion Assessment Tool: A systematic review. *Neurosurg Focus* 2016; 40:E6.
48. Ferneini EM. The financial impact of COVID-19 on our practice. *J Oral Maxillofac Surg* 2020; 78:1047-1048.
49. Sytsma TT, Greenlund LK, Greenlund LS. Joint corticosteroid injection associated with increased influenza risk. *Mayo Clin Proc Innov Qual Outcomes* 2018; 2:194-198.



