

Observational Study

## Assessment of Clinical Outcomes of Cervical Epidural Neuroplasty Using a Racz-Catheter and Predictive Factors of Efficacy in Patients with Cervical Spinal Pain

Dong Eon Moon, MD<sup>1</sup>, Hue Jung Park, MD<sup>2</sup>, and Young Hoon Kim, MD<sup>2</sup>

From: <sup>1</sup>M Pain Clinic, Seoul, Korea; <sup>2</sup>Department of Anesthesiology and Pain Medicine, Seoul St. Mary's Hospital, College of Medicine, The Catholic University of Korea, Seoul, Korea

Address Correspondence:  
Young Hoon Kim, MD  
Department of Anesthesiology and Pain Medicine  
Seoul St. Mary's Hospital,  
College of Medicine  
The Catholic University of Korea  
222 Banpo-daero  
Seocho-gu, Seoul 137-701,  
Republic of Korea  
E-mail: anekyh@catholic.ac.kr

Disclaimer: There was no external funding in the preparation of this manuscript. Conflict of interest: Each author certifies that he or she, or a member of his or her immediate family, has no commercial association (i.e., consultancies, stock ownership, equity interest, patent/licensing arrangements, etc.) that might pose a conflict of interest in connection with the submitted manuscript.

Manuscript received: 08-30-2014  
Revised manuscript received: 10-12-2014  
Accepted for publication: 10-20-2014

Free full manuscript:  
[www.painphysicianjournal.com](http://www.painphysicianjournal.com)

**Background:** Epidural neuroplasty using the Racz catheter has a therapeutic effect in patients with cervical disc herniation and central stenosis who do not respond to fluoroscopically guided epidural injections.

**Objective:** To evaluate the clinical outcomes of cervical epidural neuroplasty in patients with posterior neck and upper extremity pain and to demonstrate correlations between predictive factors and unsuccessful results of cervical epidural neuroplasty.

**Study Design:** Observational study.

**Setting:** An interventional pain management practice in a university hospital.

**Methods:** Outcome measures were obtained using the numeric rating scale (NRS) for total pain, neck pain, arm pain, and sleep disturbance; and the neck pain and disability scale (NPDS); as well as opioid consumption at preprocedure, one month, 3, 6, and 12 months after procedure. Successful epidural neuroplasty was defined as 50% or greater reduction from the preprocedure NRS for total pain, and at least a 40% reduction in the NPDS. We obtained clinical data and radiologic findings to evaluate correlations between predictive factors and efficacy of epidural neuroplasty.

**Results:** Of the 169 patients, successful outcomes were observed in 108 patients (63.9%) at one month following the procedure, in 109 patients (64.5%) at 3 months, in 96 patients (56.8%) at 6 months, and in 89 patients (52.7%) at 12 months. Previous surgery, spondylolisthesis, and ossification of the posterior longitudinal ligament were significantly associated with unsuccessful outcomes as measured by NRS and NPDS ( $P < 0.05$ ).

**Limitations:** Limitations of this evaluation include the lack of a placebo group.

**Conclusions:** Cervical epidural neuroplasty may be an effective treatment for pain reduction and functional improvement in patients with cervical spinal pain who did not respond to conservative treatment, and may decrease surgical demand. Previous surgery, spondylolisthesis, and ossification of the posterior longitudinal ligament are associated with unsuccessful outcomes of epidural neuroplasty.

**Key words:** Cervical spinal pain, epidural neuroplasty, percutaneous adhesiolysis, predictive factor, racz catheter

**Pain Physician 2015; 18:E163-E170**

**C**hronic posterior neck and upper extremity pain may result from disc herniation, discogenic pain, spondylosis, spinal stenosis, or post cervical surgery syndrome (1). Cervical epidural steroid injection is a commonly used therapy in patients with cervical disc herniation or spinal stenosis (1-11). If the injectate cannot reach the target lesion due to mechanical compression of structures on the root or epidural/perineural fibrosis, the drugs may be delivered via catheter to the intended location. Heavner et al (12) found that epidural neuroplasty reduces the need for additional treatment. Previous reports showed that epidural neuroplasty using the Racz catheter has a therapeutic effect in some patients with cervical disc herniation and central stenosis who did not respond to fluoroscopically guided epidural injections (13,14). Unsuccessful results of lumbar epidural neuroplasty are associated with previous surgery, spondylolisthesis, or foraminal stenosis in patients with lumbosacral spinal stenosis or disc herniation (15,16). However, to our knowledge, predictive risk factors for poor outcomes have not been clearly investigated for cervical epidural neuroplasty in patients with posterior neck and upper extremity pain, except for the finding that there is no correlation between grade of improvement and grade of cervical central stenosis.

The aim of this study was to evaluate clinical outcomes of cervical epidural neuroplasty in patients with posterior neck and upper extremity pain at 12 months and to demonstrate correlations between predictive factors and unsuccessful results of cervical epidural neuroplasty using the Racz catheter.

## Methods

The study was approved by the Institutional Review Board of Seoul St. Mary's Hospital, Catholic University (IRB No. KC11QISI0674), and written informed consent was obtained from all patients.

## Participants

The chronic posterior neck and upper extremity pain was diagnosed on the basis of clinical symptoms, neurological examination, and imaging studies including plain radiography, magnetic resonance imaging (MRI), or computed tomography (CT). Patients older than 20 and younger than 80 years who had herniated disc, spinal stenosis, or post cervical surgery syndrome were included in the study. Patients were consecutively included if they had pain lasting more than 3 months, which was decreased by less than 50% by 4

weeks after conservative therapy and cervical epidural steroid injection. Exclusion criteria are as follows: (a) discordance between clinical symptoms and MRI findings, (b) symptoms of myelopathy, (c) facet joint pain, (d) instability, (e) traumatic injuries, (f) bleeding tendency, (g) psychiatric disease, or (h) underlying systemic disease.

## Data Collection

We obtained clinical data such as age, gender, duration of symptoms, and history of previous cervical surgery or recommendations for surgery. Radiologic findings from plain radiography and MRI (and CT if required) were collected, including the presence of spinal cord signal change, spondylolisthesis, foraminal stenosis, and ossification of posterior longitudinal ligament (OPLL).

## MRI Findings

All patients underwent plain radiography and MRI of the cervical spine. One neuroradiologist blinded to the clinical findings evaluated the radiologic images. According to T2-weighted sagittal MRIs, cervical central stenosis was assessed by the following scale: grade 0, absence of canal stenosis; grade 1, obliteration of more than 50% of subarachnoid space; grade 2, spinal cord deformity; grade 3, spinal cord signal change (17). Spondylolisthesis was defined as a vertebral displacement exceeding 2 mm in either the anterior or posterior direction (18). Presence of foraminal stenosis or OPLL was recorded. With multilevel spinal stenosis, the level with the highest stenosis grade relevant to clinical symptoms was selected for analysis.

## Clinical Evaluation

All patients were asked to rate pain, sleep, and disability using the numeric rating scale (NRS) for total pain (NRS pain), neck pain (NRS neck), arm pain (NRS arm) and sleep disturbance (NRS sleep) as well as the Korean version of neck pain and disability scale (NPDS) (19). The ratings were performed before the procedure, and one month, 3, 6, and 12 months after the procedure on an out-patient basis by an independent assessor. The NRS represented the degree of pain or sleep disturbance with 0 as having no pain or no sleep complaints and with 100 as the worst pain imaginable or the most extreme sleep disturbance. Epidural neuroplasty was defined as successful with a 50% or more reduction from preprocedure NRS pain and with at least a 40% reduction in the NPDS. The changes in medication use

were assessed. The daily opioid intake was converted to oral morphine equivalents (20).

### Epidural Neuroplasty

Patients were prepared and draped in a sterile manner in a prone position. After skin infiltration with 1% lidocaine, a 18-gauge 3½-inch epidural needle (RX epidural needle, Coudé; Epimed International, Johnstown, NY) was inserted and pointed caudally at the level of T1-T2 interspace toward the midline under fluoroscopy. Once the placement of needle tip in the epidural space was confirmed by loss-of-resistance, the tip was rotated cephalad. This technique has been improved with the advent of the RX-2 Coudé needle, which has a second stylet that protrudes slightly beyond the tip of the needle to prevent dural cutting (21). Then, an epidural catheter (VERSA-KATH, Epimed International, Johnstown, NY) was advanced through the needle and maneuvered into the target lesion, as determined by MRI findings. Given the epidurogram with 0.5 – 1 mL of contrast media and without intravascular or subarachnoid filling, 1,500 units of hyaluronidase in 2 mL preservative-free normal saline was injected via epidural catheter. Subsequently, 2 mL mixture of 0.125% bupivacaine and 5 mg of triamcinolone was injected. In cervical epidural injections, there is a hazard of loculation which usually causes pain involving the spinal cord from compression of the blood supply. That can be relieved by flexion rotation – chin to shoulder bilaterally until lateral transforaminal run off is facilitated (14,21). Loculation is also recognized from development of peri venous counter spread which is a recognized warning sign (22). At 30 minutes after the procedure, 2 mL of 10% sodium chloride solution was infused over 30 minutes under monitoring to verify neurologic intactness. On the following day, 30 minutes after administration of 2 mL of 0.125% bupivacaine, 2 mL of 10% sodium chloride solution was infused again. After this last treatment, the catheter was removed. Heavner et al (12) performed the procedure with a 3-day protocol, and Manchikanti et al (23,24) modified the protocol from a 3-day procedure to a one-day procedure. However, our center selected a 2-day treatment regimen. Patients were asked to perform neural flossing exercises to break up weakened scar tissue and to prevent further scar tissue development (21) and were seen for follow-up one month after the procedure.

### Statistical Analysis

Given the multiple comparisons, a *P* level was adjusted ( $0.05/4 = 0.0125$ ). Wilcoxon signed rank test

was used for comparing average NRS, NPDS, and daily opioid intake at the preprocedure against one month, 3, 6, and 12 months after the procedure. The correlation between unsuccessful results of cervical epidural neuroplasty and predictive factors such as gender, age, duration of symptoms, presence of spinal cord signal change, previous surgery, spondyloolsthesis, OPLL, or foraminal stenosis was analyzed by forward stepwise method in logistic regression analysis. Statistical analysis was performed using the SPSS version 18 (SPSS, Inc., Chicago, IL). A *P* value < 0.05 was considered statistically significant.

### Results

Of the 196 patients assessed for eligibility, 27 patients met exclusion criteria and 6 patients, including one death due to cancer, were lost to follow-up after the procedure. The remaining 169 patients (95 women, 74 men) with a mean age of  $51.7 \pm 10.5$  years excluding 27 patients were included in analysis. Of these, the average duration of symptoms was  $51.5 \pm 54.7$  months. One-hundred-eighteen patients had spinal stenosis, 32 patients had herniated disc, and, 19 patients had post cervical surgery syndrome. Forty-six patients (27.2%) was recommended an operation for pain relief at other hospitals. Cervical canals on MRI were assessed as grade 1, grade 2, and grade 3 stenosis in 81, 77, and 11 patients, respectively. Spondyloolsthesis, foraminal stenosis, and OPLL were present in 23, 88, and 11 patients, respectively (Table 1).

Successful outcomes (at least 50% reduction in NRS for pain and 40% reduction in the NPDS) were observed in 108 patients (63.9%) at one month following the procedure, in 109 patients (64.5%) at 3 months, in 96 patients (56.8%) at 6 months, and in 89 patients (52.7%) at 12 months (Fig. 1). Three patients underwent surgery due to severe pain during the follow-up period. There was no adverse event except for transient local pain associated with the procedure.

Of 46 patients who had received a recommendation for surgery, successful outcomes were obtained for 27 patients (58.7%) at one month after the procedure, in 26 patients (56.5%) at 3 months, in 21 patients (45.7%) at 6 months, and in 20 patients (43.5%) at 12 months.

At preprocedure, there were no significant differences in gender ratio, age, duration of symptoms, opioid intake, NRS pain, NRS neck, NRS arm, NRS sleep, and NPDS between patients with and without successful outcomes. NRS pain, NRS neck, NRS arm, NRS sleep,

and NPDS were significantly decreased at one month, 3, 6, and 12 months as compared to those at preprocedure ( $P < 0.001$ ; Table 2).

Daily opioid intake was reduced at one, 3, 6, and 12 month follow-up periods compared to baseline ( $P < 0.001$ ; Table 3).

Table 4 lists variables that were significantly associated with unsuccessful epidural neuroplasty in logistic

regression analysis. There were no correlation with gender, age, duration of symptoms, presence of spinal cord signal change, foraminal stenosis, or cervical stenosis grade (Table 5).

## Discussion

This study showed that epidural neuroplasty in patients with chronic posterior neck and upper extremity pain resulted in reduced neck and arm pain at one month after the procedure, and that these improvements were maintained at 12 months after epidural neuroplasty, which is consistent with findings from prior studies (13,14). With regard to functional outcomes, NRS for sleep and NPDS were reduced and maintained during the study periods as well. Since these clinical outcomes were obtained for patients with symptoms refractory

Table 1. Characteristics of patients.

Characteristic		n = 169
Age (years)		51.7 ± 10.5
Sex (female/male)		95/74
Duration of Symptoms (months)		51.5 ± 54.7
Diagnosis	Herniated Disc	32 (18.9)
	Spinal Stenosis	118 (69.8)
	Post Cervical Surgery Syndrome	19 (11.2)
Recommendations for Surgery		46 (27.2)
MRI Grade Of Cervical Canal Stenosis	Grade 0	0 (0)
	Grade 1	81 (47.9)
	Grade 2	77 (45.6)
	Grade 3	11 (6.5)
Spondylolisthesis		23 (13.6)
Foraminal Stenosis		88 (52.1)
OPLL		11 (6.5)

Data represent the mean ± SD, number or frequency (percentage). OPLL = ossification of posterior longitudinal ligament, SD = standard deviation.

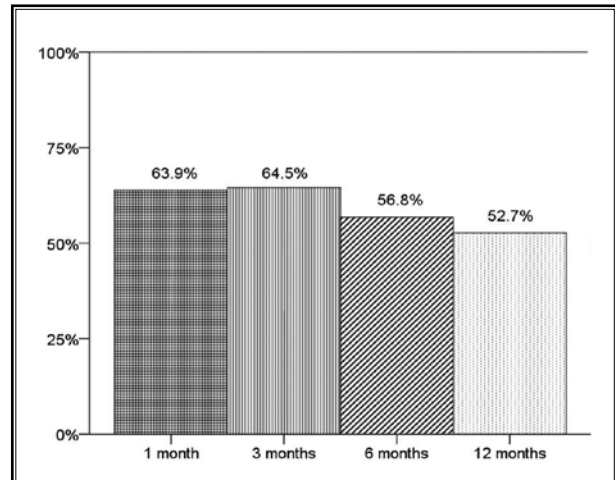


Fig. 1. Proportion of patients with significant relief with numeric rating scale (NRS) ≥ 50% and neck pain and disability scale (NPDS) of ≥ 40%.

Table 2. Comparisons of NRS Pain, NRS Neck, NRS Arm, NRS Sleep, and NPDS between preprocedure.

	Preprocedure (169)	1 month (169)	3 months (169)	6 months (166)	12 months (163)	P value
NRS Pain	70.4 ± 13.5	36.8 ± 20.5	33.1 ± 21.9	35.6 ± 24.1	37.6 ± 25.5	< 0.001*
NRS Neck	61.2 ± 23.6	31.7 ± 22.3	28.7 ± 22.8	30.9 ± 24.8	32.3 ± 25.4	< 0.001*
NRS Arm	54.6 ± 27.6	28.2 ± 22.0	25.6 ± 22.9	26.3 ± 23.5	27.6 ± 25.8	< 0.001*
NRS Sleep	43.7 ± 30.8	22.4 ± 24.0	18.9 ± 22.1	17.9 ± 22.7	17.4 ± 22.9	< 0.001*
NPDS	65.8 ± 13.0	38.6 ± 19.4	36.0 ± 19.8	37.0 ± 21.0	37.3 ± 22.1	< 0.001*

Values are mean values ± SD. NRS = numerical rating scale, NPDS = neck pain and disability scale, SD = standard deviation, Wilcoxon signed rank test to compare mean ± SD. P value (< 0.0125 [= 0.05/4]) for the difference at postprocedural one month, and 3, 6, 12 months versus preprocedural values. \*Indicates significant difference.

## Epidural Neuroplasty in Cervical Spinal Pain

Table 3. Daily opioid intake (oral morphine equivalence mg).

	Preprocedure	1 month	3 months	6 months	12 months	P value
Opioid intake (Oral morphine equivalence mg)	57.2 ± 12.8	33.4 ± 19.5	29.4 ± 20.2	30.6 ± 21.6	31.2 ± 21.8	< 0.001*

Values are mean ± SD. Wilcoxon signed rank test to compare mean ± SD. P value (< 0.0125 [= 0.05/4]) for the difference at postprocedural one month, and 3, 6, 12 months versus preprocedural values. \*Indicates significant difference.

Table 4. Logistic regression results for predicting unsuccessful epidural neuroplasty.

Variable	1 month			3 months			6 months			12 months		
	B	OR (95% CI)	P	B	OR (95% CI)	P	B	OR (95% CI)	P	B	OR (95% CI)	P
Previous surgery	-	-	-	1.347	3.848 (1.263 - 11.724)	0.018*	1.749	5.749 (1.765 - 18.727)	0.004*	1.384	3.992 (1.191 - 13.386)	0.025*
Spondylolisthesis	1.142	3.133 (1.203 - 8.159)	0.019*	1.015	2.759 (1.047 - 7.273)	0.040*	1.100	3.005 (1.154 - 7.825)	0.024*	1.062	2.892 (1.068 - 7.831)	0.037*
OPLL	2.132	8.430 (1.660 - 42.807)	0.010*	2.142	8.520 (1.639 - 44.279)	0.011*	1.795	6.017 (1.194 - 30.318)	0.030*	1.552	4.722 (0.911 - 24.464)	0.064

OPLL = ossification of posterior longitudinal ligament, B = regression coefficient, OR = odds ratio, CI = confidence interval. The correlation between unsuccessful results of epidural neuroplasty and predictive variables such as sex, age, duration of symptoms, presence of spinal cord signal change, previous surgery, spondylolisthesis, OPLL, or foraminal stenosis was analyzed by forward stepwise method in logistic regression analysis. Forward stepwise method in logistic regression analysis was used. \*Indicates significant difference.

Table 5. Logistic regression results between cervical stenosis grade and predicting unsuccessful epidural neuroplasty.

Variable	1 month			3 months			6 months			12 months		
	B	OR (95% CI)	P	B	OR (95% CI)	P	B	OR (95% CI)	P	B	OR (95% CI)	P
> Grade 2	0.439	1.551 (0.822 - 2.925)	0.175	0.497	1.644 (0.868 - 3.114)	0.127	0.290	1.336 (0.725 - 2.462)	0.353	-0.062	0.939 (0.513 - 1.719)	0.839

B = regression coefficient, OR = odds ratio, CI = confidence interval. Logistic regression analysis was used.

to cervical epidural injection, epidural neuroplasty can be recommended after failure of cervical epidural injection. Advancing the catheter in epidural neuroplasty increases the chance of delivering the injectate toward the ventral epidural space or nerve root because the tip of the catheter can be placed more laterally than the needle tip during cervical interlaminar epidural injection. Stojanovic et al (25) found that the presence of contrast media in the ventral epidural space was observed in only 28% patients after cervical interlaminar epidural injection. Racz et al (21) recommended that the catheter be advanced to the lateral gutter to get runoff of contrast out of the foramen without loculation of contrast. The mechanism of action of hypertonic saline remains controversial. Hypertonic saline reduces cell swelling which reduces pressure on the nerve (15,23). Also, it was shown that hypertonic saline decreased spinal-cord water content (16,23). In in-vitro study,

hypertonic saline inhibits fibrocyte regeneration (26). Hypertonic saline also augments local anesthetic action (18,27). Even though the clinical efficacy of hypertonic saline has been shown in several studies (12,28,29), these actions of hypertonic saline in epidural neuroplasty have remained speculative. We are reluctant to inject hypertonic saline by a single-shot bolus during cervical epidural injection because of potential adverse effects associated. Therefore, we inserted the catheter and confirmed that it was not located within a vessel or subarachnoid space prior to the injection of hypertonic saline. The major risk of the procedure is subarachnoid injection of hypertonic saline. The procedure was designed to minimize that risk.

Epidural fibrosis is a common finding after lumbar discectomy (30) and can be also occur in the absence of previous surgery (31). The association between epidural fibrosis and radicular pain is controversial. Ross

et al (32) and Sen et al (33) suggested that there was a significant association between the presence of epidural fibrosis and the occurrence of recurrent radicular pain. Coskun et al (34) found that there was no relationship between the severity of epidural fibrosis and pain scores or disability scores. Epidural fibrosis may be identified with intravenous contrast-enhanced MRI (32,33). An epidurogram may be used for clarification. The presence of epidural fibrosis is elucidated by a lack of epidural contrast flow into epidural finger projections (21). Fibrosis induces a tension and a compression injury to the nerve root, and increases the excitability of the nerve root (35,36). It disturbs the cerebrospinal fluid-mediated nourishment, causes neural damage, and decreases the efficacy of a treatment due to the difficulty in distribution of medications (37). Injected hyaluronidase makes adhesiolysis of the target site partially possible, although mechanical adhesiolysis used for lumbar epidural neuroplasty using NaviCath is impossible in the cervical region. It facilitates the spread of local anesthetic and glucocorticoid, and heightens the effect of medications. Adhesiolysis serves as a fluid foraminotomy attenuating foraminal stenosis caused by epidural fibrosis and as a decompression of distended epidural venous structures that may compress the nerves and result in needle stick related epidural hematomas (21).

The Racz catheter is radiopaque and resistant due to the internal coil spring; hence, catheter tip placement at the target site is more precise as compared with non-radiopaque epidural catheter. Unlike the Tuohy needle, the improvement of the RX epidural needle may lessen catheter shearing caused by a repeated back and forth movement of the catheter through the needle (38).

In our study, history of previous surgery, spondylolisthesis, and OPLL were significantly correlated with unsuccessful epidural neuroplasty, while age, gender, duration of symptoms, spinal cord signal change, or foraminal stenosis were not associated with poor prognosis. Previous operations on the cervical spine can cause epidural scarring or adhesion of nerve roots to the disc or pedicle, and lead to nerve injury. Scar formation can hinder the spread of injected drugs and effective adhesiolysis (39). The presence of spondylolisthesis, which was observed in 20% of symptomatic patients, is associated with increased segmental instability and decreased cross-sectional area of spinal canal diameter (18). Cervical OPLL may compress spinal cord and nerve roots, which also causes a reduction of cross-sectional area of spinal canal diameter. In this study, however,

cervical central stenosis grades were not associated with outcomes of epidural neuroplasty, which is similar to findings from a prior study (34). Although we are unable to fully explain the reasons for this phenomenon, it might be because inflammation of compressed nerve roots was a critical reason for pain (6). In addition, uniplanar spinal canal dimension on static images used for grading in this study did not fully reflect dynamic stenosis which patients with spondylolisthesis might have. Structural characteristics of scar formation, spondylolisthesis, and OPLL could disrupt catheter access and spread of injectate, which explained why patients with previous surgery, spondylolisthesis, or OPLL experienced relatively unsuccessful outcomes compared with those without.

Cervical radiculopathy may result from cervical foraminal stenosis, which causes nerve root compression (40). Thus, our expectation was that patients with foraminal stenosis would experience poorer outcomes, but there was no correlation between foraminal stenosis and poor outcome in the analysis. In many cases, runoffs of contrast out of the foramen were observed despite the presence of foraminal stenosis, which might lead to successful epidural neuroplasty. Furthermore, we used T2-weighted axial images for MRI grading system, while Park et al (40) suggested T2-weighted oblique sagittal images for evaluation of cervical foraminal stenosis.

Spinal cord signal change in MRI may result from spondylolisthesis or OPLL, and be related with poor surgical outcomes (28,41,42). In this study, spinal cord signal change was not associated with unsuccessful outcomes, which might be attributed to exclusion of patients with symptoms of myelopathy. None of the patients with spinal cord signal change had abnormalities of motor or sensory functions in upper and lower extremities or in the bladder.

In our current study, successful outcomes were obtained in about half of the 46 patients who had initially received a recommendation for surgical intervention. Therefore, cervical epidural neuroplasty can be a treatment option prior to considering surgery. This recommendation is similar to the study by Gerdsmeyer et al (43) that the lumbar epidural lysis of adhesion should be the first recommended option for patients with chronic lumbosacral radicular pain. Further studies are warranted about cost effectiveness of cervical epidural neuroplasty because of the long duration of action and reduced need for additional procedures.

There were several limitations in this study. First,

we did not include a control group. Secondly, this study included the patients with spinal stenosis, herniated disc, and post cervical surgery syndrome in analyzing data without classifying each diagnosis. In spite of these limitations, we evaluated for the first time the relationship between epidural neuroplasty outcomes and prognostic predictive factors in patients with cervical spinal pain.

## Conclusions

In conclusion, cervical epidural neuroplasty with the Racz catheter is effective for pain reduction and functional improvement in patients with chronic posterior neck and upper extremity pain refractory to conservative treatment, and decreases the need for surgical treatment. Previous surgery, spondylolisthesis, and OPLL are associated with unsuccessful outcomes after cervical epidural neuroplasty.

## References

1. Manchikanti L, Abdi S, Atluri S, Benyamin RM, Boswell MV, Buenaventura RM, Bryce DA, Burks PA, Caraway DL, Calodney AK, Cash KA, Christo PJ, Cohen SP, Colson J, Conn A, Corder H, Coubarous S, Datta S, Deer TR, Diwan S, Falco FJ, Fellows B, Geffert S, Grider JS, Gupta S, Hameed H, Hameed M, Hansen H, Helm S, 2nd, Janata JW, Justiz R, Kaye AD, Lee M, Manchikanti KN, McManus CD, Onyewu O, Parr AT, Patel VB, Racz GB, Sehgal N, Sharma ML, Simopoulos TT, Singh V, Smith HS, Snook LT, Swicegood JR, Vallejo R, Ward SP, Wargo BW, Zhu J, Hirsch JA. An update of comprehensive evidence-based guidelines for interventional techniques in chronic spinal pain. Part II: Guidance and recommendations. *Pain Physician* 2013; 16:S49-S283.
2. Candido KD, Knezevic N. Cervical epidural steroid injections for the treatment of cervical spinal (neck) pain. *Curr Pain Headache Rep* 2013; 17:314.
3. Diwan S, Manchikanti L, Benyamin RM, Bryce DA, Geffert S, Hameed H, Sharma ML, Abdi S, Falco FJ. Effectiveness of cervical epidural injections in the management of chronic neck and upper extremity pain. *Pain Physician* 2012; 15:E405-E434.
4. Huston CW. Cervical epidural steroid injections in the management of cervical radiculitis: Interlaminar versus transforaminal. A review. *Current Reviews in Musculoskeletal Medicine* 2009; 2:30-42.
5. Kwon JW, Lee JW, Kim SH, Choi JY, Yeom JS, Kim HJ, Kwack KS, Moon SG, Jun WS, Kang HS. Cervical interlaminar epidural steroid injection for neck pain and cervical radiculopathy: Effect and prognostic factors. *Skeletal Radiol* 2007; 36:431-436.
6. Lee SH, Kim KT, Kim DH, Lee BJ, Son ES, Kwack YH. Clinical outcomes of cervical radiculopathy following epidural steroid injection: A prospective study with follow-up for more than 2 years. *Spine (Phila Pa 1976)* 2012; 37:1041-1047.
7. Manchikanti L, Cash KA, Pampati V, Wargo BW, Malla Y. Management of chronic pain of cervical disc herniation and radiculitis with fluoroscopic cervical interlaminar epidural injections. *International Journal of Medical Sciences* 2012; 9:424-434.
8. Manchikanti L, Falco FJ, Diwan S, Hirsch JA, Smith HS. Cervical radicular pain: The role of interlaminar and transforaminal epidural injections. *Curr Pain Headache Rep* 2014; 18:389.
9. Manchikanti L, Malla Y, Cash KA, McManus CD, Pampati V. Fluoroscopic epidural injections in cervical spinal stenosis: Preliminary results of a randomized, double-blind, active control trial. *Pain Physician* 2012; 15:E59-E70.
10. Pasqualucci A, Varrassi G, Braschi A, Peduto VA, Brunelli A, Marinangeli F, Gori F, Colo F, Paladini A, Mojoli F. Epidural local anesthetic plus corticosteroid for the treatment of cervical brachial radicular pain: Single injection versus continuous infusion. *Clin J Pain* 2007; 23:551-557.
11. Stout A. Epidural steroid injections for cervical radiculopathy. *Phys Med Rehabil Clin N Am* 2011; 22:149-159.
12. Heavner JE, Racz GB, Raj P. Percutaneous epidural neuroplasty: Prospective evaluation of 0.9% NaCl versus 10% NaCl with or without hyaluronidase. *Reg Anesth Pain Med* 1999; 24:202-207.
13. Park EJ, Park SY, Lee SJ, Kim NS, Koh do Y. Clinical outcomes of epidural neuroplasty for cervical disc herniation. *J Korean Med Sci* 2013; 28:461-465.
14. Park CH, Lee SH, Lee SC. Preliminary results of the clinical effectiveness of percutaneous adhesiolysis using a Racz catheter in the management of chronic pain due to cervical central stenosis. *Pain Physician* 2013; 16:353-358.
15. Jewett DL, King JS. Conduction block of monkey dorsal rootlets by water and hypertonic saline solutions. *Experimental Neurology* 1971; 33:225-237.
16. Rojiani AM, Cho ES, Sharer L, Prineas JW. Electrolyte-induced demyelination in rats. 2. Ultrastructural evolution. *Acta Neuropathologica* 1994; 88:293-299.
17. Lewis RN. The use of combined suprascapular and circumflex (articular branches) nerve blocks in the management of chronic arthritis of the shoulder joint. *Eur J Anaesthesiol* 1999; 16:37-41.
18. King JS, Jewett DL, Sundberg HR. Differential blockade of cat dorsal root C fibers by various chloride solutions. *J Neurosurg* 1972; 36:569-583.
19. Lee H, Nicholson LL, Adams RD, Maher CG, Halaki M, Bae SS. Development and psychometric testing of Korean language versions of 4 neck pain and disability questionnaires. *Spine (Phila Pa 1976)* 2006; 31:1841-1845.
20. Pereira J, Lawlor P, Vigano A, Dorgan M, Bruera E. Equianalgesic dose ratios for opioids. A critical review and proposals for long-term dosing. *J Pain Symptom Manage* 2001; 22:672-687.
21. Racz GB, Day MR, Heavner JE, Smith JP, Scott J, Noe CE, Nagy L, Ilnert H. Epidural Lysis of Adhesions and Per-

- cutaneous Neuroplasty, Pain Management - Current Issues and Opinions (Ed). InTech 2012; DOI: 10.5772/39173. www.intechopen.com/books/pain-management-current-issues-and-opinions/epidural-lysis-of-adhesions-and-percutaneous-neuroplasty
22. Racz GB, Heavner JE. Cervical spinal canal loculation and secondary ischemic cord injury – PVCS – perivenous counter spread – danger sign! *Pain Pract* 2008; 8:399-403.
  23. Manchikanti L, Bakhit CE. Percutaneous lysis of epidural adhesions. *Pain Physician* 2000; 3:46-64.
  24. Manchikanti L, Pampati V, Fellows B, Rivera J, Beyer CD, Damron KS. Role of one day epidural adhesiolysis in management of chronic low back pain: A randomized clinical trial. *Pain Physician* 2001; 4:153-166.
  25. Stojanovic MP, Vu TN, Caneris O, Slezak J, Cohen SP, Sang CN. The role of fluoroscopy in cervical epidural steroid injections: an analysis of contrast dispersal patterns. *Spine (Phila Pa 1976)* 2002; 27:509-514.
  26. Birkenmaier C, Redeker J, Sievers B, Melcher C, Jansson V, Mayer-Wagner S. An evaluation of medications commonly used for epidural neurolysis procedures in a human fibroblast cell culture model. *Reg Anesth Pain Med* 2011; 36:140-144.
  27. Anderson SR, Racz GB, Heavner J. Evolution of epidural lysis of adhesions. *Pain Physician* 2000; 3:262-270.
  28. Manchikanti L, Rivera JJ, Pampati V, Damron KS, McManus CD, Brandon DE, Wilson SR. One day lumbar epidural adhesiolysis and hypertonic saline neurolysis in treatment of chronic low back pain: a randomized, double-blind trial. *Pain Physician* 2004; 7:177-186.
  29. Veihelmann A, Devens C, Trouillier H, Birkenmaier C, Gerdsmeyer L, Refior HJ. Epidural neuroplasty versus physiotherapy to relieve pain in patients with sciatica: A prospective randomized blinded clinical trial. *J Orthop Sci* 2006; 11:365-369.
  30. Fritsch EW, Heisel J, Rupp S. The failed back surgery syndrome: reasons, intraoperative findings, and long-term results: A report of 182 operative treatments. *Spine (Phila Pa 1976)* 1996; 21:626-633.
  31. Cooper RG, Freemont AJ, Hoyland JA, Jenkins JP, West CG, Illingworth KJ, Jayson MI. Herniated intervertebral disc-associated periradicular fibrosis and vascular abnormalities occur without inflammatory cell infiltration. *Spine (Phila Pa 1976)* 1995; 20:591-598.
  32. Ross JS, Robertson JT, Frederickson RC, Petrie JL, Obuchowski N, Modic MT, deTribolet N. Association between peridural scar and recurrent radicular pain after lumbar discectomy: Magnetic resonance evaluation. ADCON-L European Study Group. *Neurosurgery* 1996; 38:855-861; discussion 861-853.
  33. Sen O, Kizilkilic O, Aydin MV, Yalcin O, Erdogan B, Cekinmez M, Caner H, Altinors N. The role of closed-suction drainage in preventing epidural fibrosis and its correlation with a new grading system of epidural fibrosis on the basis of MRI. *Eur Spine J* 2005; 14:409-414.
  34. Coskun E, Suzer T, Topuz O, Zencir M, Pakdemirli E, Tahta K. Relationships between epidural fibrosis, pain, disability, and psychological factors after lumbar disc surgery. *Eur Spine J* 2000; 9:218-223.
  35. Kuslich SD, Ulstrom CL, Michael CJ. The tissue origin of low back pain and sciatica: A report of pain response to tissue stimulation during operations on the lumbar spine using local anesthesia. *Orthop Clin North Am* 1991; 22:181-187.
  36. Lee F, Jamison DE, Hurley RW, Cohen SP. Epidural lysis of adhesions. *Korean J Pain* 2014; 27:3-15.
  37. Hoyland JA, Freemont AJ, Jayson MI. Intervertebral foramen venous obstruction. A cause of periradicular fibrosis? *Spine (Phila Pa 1976)* 1989; 14:558-568.
  38. Racz GB, Heavner JE, Trescot A. Percutaneous lysis of epidural adhesions – evidence for safety and efficacy. *Pain Pract* 2008; 8:277-286.
  39. Manchikanti L, Singh V, Cash KA, Pampati V, Datta S. A comparative effectiveness evaluation of percutaneous adhesiolysis and epidural steroid injections in managing lumbar post surgery syndrome: A randomized, equivalence controlled trial. *Pain Physician* 2009; 12:E355-E368.
  40. Park HJ, Kim SS, Lee SY, Park NH, Chung EC, Rho MH, Kwon HJ, Kook SH. A practical MRI grading system for cervical foraminal stenosis based on oblique sagittal images. *Br J Radiol* 2013; 86:20120515.
  41. Kawasaki M, Tani T, Ushida T, Ishida K. Anterolisthesis and retrolisthesis of the cervical spine in cervical spondylotic myelopathy in the elderly. *J Orthop Sci* 2007; 12:207-213.
  42. Wada E, Yonenobu K, Suzuki S, Kanazawa A, Ochi T. Can intramedullary signal change on magnetic resonance imaging predict surgical outcome in cervical spondylotic myelopathy? *Spine (Phila Pa 1976)* 1999; 24:455-461; discussion 462.
  43. Gerdsmeyer L, Wagenpfeil S, Birkenmaier C, Veihelmann A, Hauschild M, Wagner K, Muderis MA, Gollwitzer H, Diehl P, Toepfer A. Percutaneous epidural lysis of adhesions in chronic lumbar radicular pain: A randomized, double-blind, placebo-controlled trial. *Pain Physician* 2013; 16:185-196.